

Imaging in Cardiology: "Impossible" Pacemaker-Mediated Tachycardia during Implantation

J.C.J. RES, R. ABELS, G. KROON
Department of Cardiology, Zaans Medical Center, de Heel, Zaandam, The Netherlands

Introduction

Pacemaker implantation can be accompanied by different types of arrhythmias. In most cases, short-lived atrial or ventricular arrhythmias induced by the mechanical contact of a manipulated electrode are involved. In many cases, the ventricular arrhythmias consist of ventricular extrasystolic beats. Few cases report on persistent ventricular arrhythmias during pacemaker implantation. In this case report, we describe the occurrence of a typical ventricular arrhythmia in the form of a pacemaker-mediated tachycardia, which was thought to be impossible. It occurred when the atrial and ventricular leads were connected to the pacemaker, which was programmed in the unipolar pacing configurations.

Case Report

A 78-year-old man was referred for pacemaker implantation due to symptomatic 3rd degree atrioventricular (AV) block. Neither the patient's history nor physical examination revealed abnormalities with regard to his cardiovascular status. Tachyarrhythmias such as intermittent atrial fibrillation or ventricular tachycardia had not been documented in recent years, and the patient was not on medication. A 24-hour ambulatory electrocardiogram indicated permanent AV block in the presence of normal sinus rhythm.

The atrial and ventricular leads were implanted via the cephalic vein without complications. The tip of the atrial lead (Arox, Biotronik, Germany) was positioned at the right atrial appendage. The acute atrial measurements were: threshold at 0.7 V with a pulse duration of 0.4 ms, a pacing impedance of 480 Ω , and a P-wave of 2.8 mV. The tip of the ventricular lead (Merox, Biotronik) was implanted at the right ventricular apex, and the measurements were: 0.4 V at 0.4 ms for the stimulation threshold, a pacing impedance of 920 Ω , and sensed R-wave amplitudes equal or greater than 12.8 mV.

The atrial lead was connected to the Philos DR pacemaker (Biotronik) before the ventricular lead was connected. Immediately after fixation of the connector screw of the ventricular lead, a ventricular rhythm was present without pacing artefacts, but the ventricular complex was identical to the paced ventricular complexes observed during the stimulation threshold test (see Figure 1). It has to be stressed that the pacemaker was not inserted into the pocket, and the skin of the patient was covered with an antiseptic foil. Furthermore, the pacemaker was not reprogrammed and, therefore, the default pacemaker program was active: Pacing and sensing in the atrium and ventricle were in the unipolar configurations. When the ventricular pacemaker lead was disconnected, the tachycardia disappeared instantly and did not restart. After reconnecting the lead, a similar ventricular tachycardia was noticed. A pacemaker-mediated tachycardia was suspected, and the atrial lead was hooked up in parallel to the lead used for intracardiac monitoring during implantation in order to visualize detected atrial signal (V6 lead in Figure 2). The V6-lead showed a ventricu-

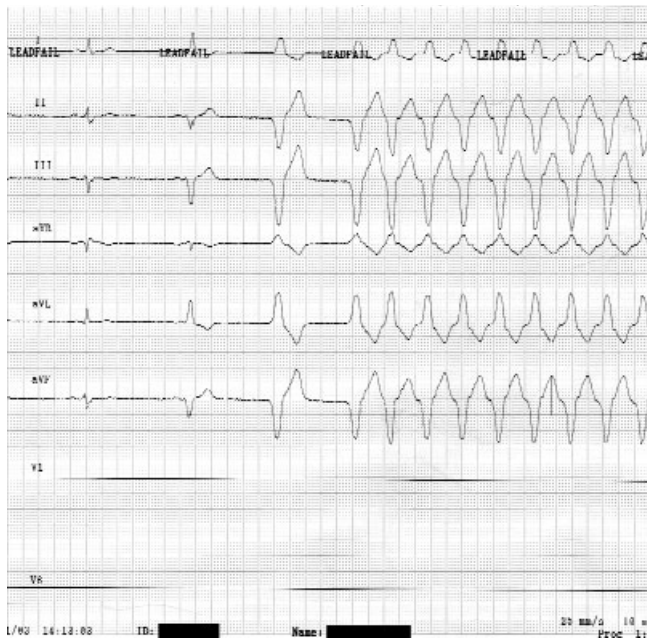

Figure 1. After a "narrow" ventricular escape beat, a fusion complex and a wide paced QRS complex are seen before the onset of ventricular tachycardia. Since the ventricular complex is similar to that of the paced ventricular complex, a pacemaker-mediated tachycardia is presumed.

lar pacing artefact, ventricular activation, and a marked P-wave just after the paced ventricular QRS complex. The tachycardia stopped after a failed retrograde conduction, which was followed by an atrial pacing artefact without atrial capture (Figure 3). The triggering of the ventricular QRS complex without preceding atrial capture was the required condition for the initiation of a pacemaker-mediated tachycardia. In this case, no antegrade invasion of the AV node enables retrograde conduction of the ventricular activation over the AV node to the atrium (in the presence of complete AV block). After disconnecting the atrial lead or the ventricular lead, the tachycardia ceased and did not recur. It was presumed that, under normal conditions, the implanted pacemaker can cause no pacemaker-mediated tachycardia, and the implantation was concluded routinely (Figure 4). Further tachycardias were not observed.

Discussion

The occurrence of the pacemaker-mediated tachycardia in our patient was related to the retrograde conduction of paced ventricular activation in the presence

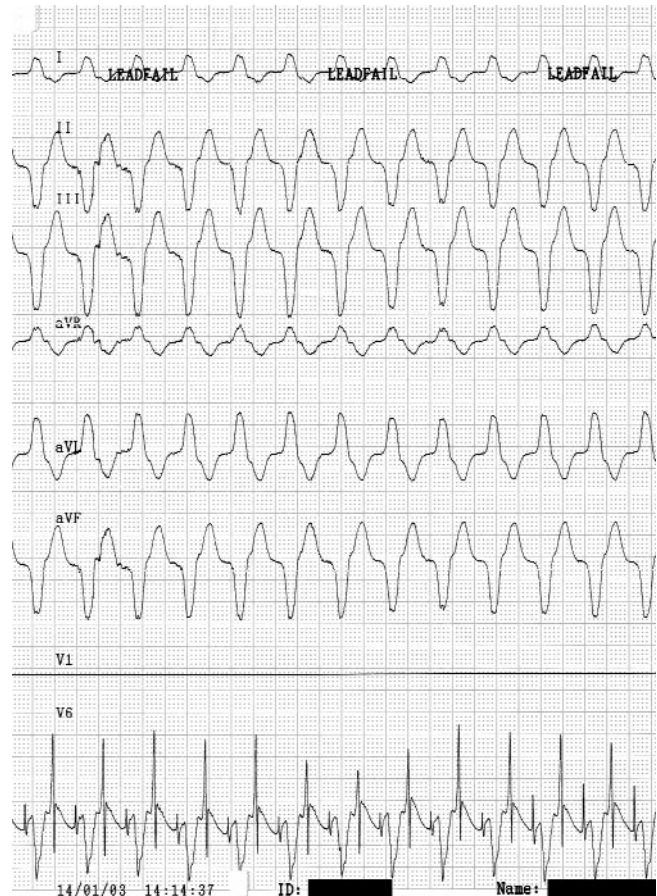


Figure 2. Continuous tachycardia with QRS complexes similar to the paced ventricular QRS complexes. The intracardiac V6-lead recording reveals a large P-wave directly after the ventricular QRS complex.

of a total AV block, following lack of atrial capture. The tachycardia was initiated in the unipolar atrial and ventricular pacing and sensing configuration, although the pacemaker was not inserted into the pacemaker pocket.

Pacemaker-mediated tachycardias are basically initiated when retrogradely conducted R-waves are sensed in the atrium, followed by normal ventricular stimulation after the programmed AV delay. Retrograde (VA) conduction is a prerequisite for this form of tachycardias. Cazeau et al. [1] found VA conduction in 7/17 patients (41%) at rest, and in 13/17 patients (76%) at the end of a special study protocol. Others have found similar rates in patients with complete AV block [2-4]. By comparison, two-thirds of patients with sinus node disease exhibited VA conduction [2].

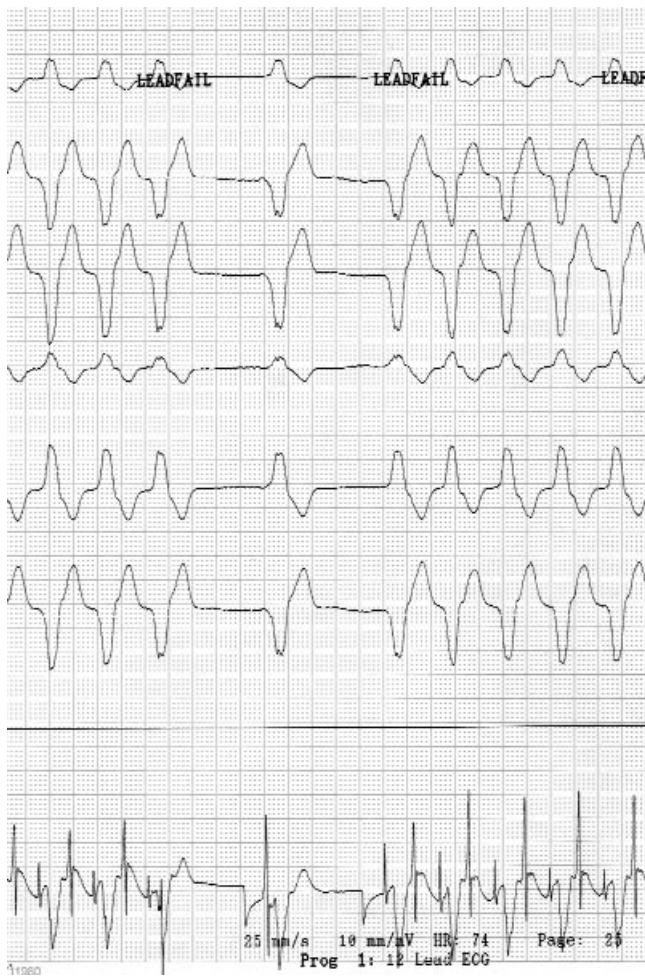


Figure 3. Surface ECG using limb leads and intracardiac ECG (the bottom line) illustrate the pacemaker-mediated tachycardia. The tachycardia is maintained by a retrogradely conducted P-wave, and it stops after a blocked P-wave. After the temporary end of tachycardia in the intracardiac ECG, the following items can be discerned: An atrial stimulus artefact without capture, followed by an atrial activation superimposed on a ventricular stimulus artefact and ventricular activation. The next cycle shows an atrial stimulus artefact without capture and a ventricular stimulus artefact resulting in capture, immediately followed by a retrogradely conducted P-wave and subsequent reinitiation of tachycardia.

Today, most pacemakers incorporate algorithms to prevent or terminate ongoing pacemaker-mediated tachycardia. However, the incidence of pacemaker-mediated tachycardia is reported to be low irrespective of whether preventive algorithms are activated or not. Longo et al. [5] observed pacemaker-mediated tachycardia in two out of 420 patients, and Araya Gomez et al. [6] in one

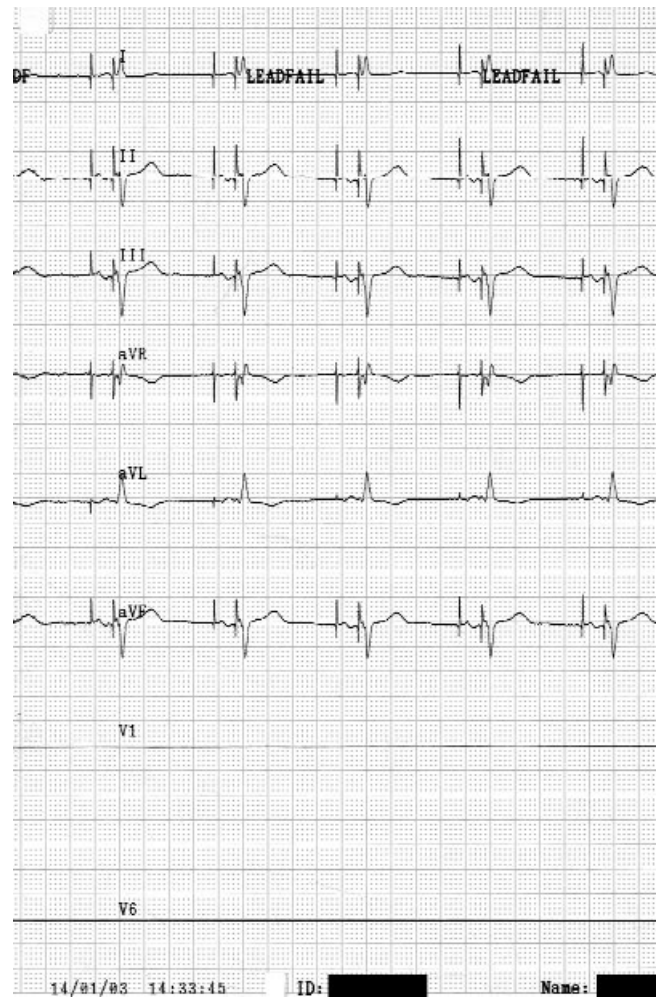


Figure 4. DDD pacemaker rhythm is present. Note the marked (unipolar) pacing artefacts before the atrial and ventricular complexes.

out of 66. Although pacemaker-mediated tachycardias are very unlikely to occur in patients without VA conduction, Jordaens et al. [7] described a case with negative testing on VA conduction and a pacemaker-mediated tachycardia during follow-up.

Pacemaker-mediated tachycardias must be differentiated from atrial tachycardias. Recording the atrial activation is pivotal for the diagnosis of this kind of tachycardia. To this end, transesophageal recordings [8] or intracardiac electrocardiograms provided by the pacemakers [9] have been used. In this case, we inserted the screwdriver into the atrial pacemaker connector and attached an intracardiac ECG lead to the screwdriver. In this way we managed to visualize the signal sensed in the atrium without interrupting the pacemaker and lead integrity.

Pacemaker-mediated tachycardia may be induced by atrial pacing without capture or by sensing of false atrial signals that trigger an AV delay followed by ventricular stimulation and activation. In this case, two questions arise: Why is it possible that the ventricular stimulus is followed by ventricular activation, and why is the atrial stimulus not followed by an atrial activation? It must be emphasized that the pacemaker was programmed to the unipolar sensing and pacing configuration (according the default pacemaker program) in the DDD mode. The possibility of ventricular capture without atrial capture is dependent on a low ventricular stimulation threshold and a high-resistance common ground of the atrial and ventricular channels in the pacemaker. Thus, sensing atrial and ventricular signals seems to be possible with this high-resistant connection between the atrial and ventricular channels. This concept was confirmed by the finding that ventricular stimulation was ineffective with either the atrial or the ventricular lead disconnected from the pacemaker. Furthermore, the intracardiac ECG showed atrial and ventricular pacing artefacts at the appropriate timing. Both pacing artefacts were not visible on the surface ECG before insertion of the pacemaker into the pocket. After insertion, the pacemaker artefacts were clearly visible (Figure 4).

Conclusion

An "impossible" pacemaker-mediated tachycardia was observed during implantation, which was facilitated by the following conditions:

- Propensity for retrograde (VA) conduction in the presence of a complete antegrade AV block;
- Possibility of ventricular stimulation in a unipolar pacing configuration due to a low pacing threshold and the "common ground" in a DDD pacemaker, although the pacemaker was not inserted into the pocket;
- Absence of antegrade conduction into the AV node in cases where atrial stimulation was not followed by atrial activation.

References

- [1] Cazeau S, Daubert C, Mabo P, et al. Dynamic electrophysiology of ventriculoatrial conduction: implications for DDD and DDDR pacing. *PACE*. 1990; 13: 1646-1655.
- [2] Marco DD, Gallagher D. Noninvasive measurement of retrograde conduction times in pacemaker patients. *PACE*. 1988; 11: 1673-1678.
- [3] van Mechelen R, Hagemeyer F, de Jong J, et al. Responses of an AV universal (DDD) pulse generator (Cordis 233D) to programmed single ventricular extrastimuli. *PACE*. 1984; 7: 215-226.
- [4] Jordaens L, Clement DL. The prevention of pacemaker mediated tachycardias in double-chamber pacing. *Acta Cardiol* 1984; 39: 449-462.
- [5] Longo E, Catrini V. Experience and implantation techniques with a new single-pass lead VDD pacing system. *PACE* 1990; 13: 927-936.
- [6] Araya Gomez V, Lopez Barreiro L, Gonzalez-Hermosillo JA, et al. The DDD pacemaker implanted intravenously. *Arch Inst Cardiol Mex*. 1995; 65: 121-129.
- [7] Jordaens L, Robbens E, Van Wassenhove E, et al. Incidence of arrhythmias after atrial or dual-chamber pacemaker implantation. *Eur Heart J*. 1989; 10: 102-107.
- [8] Pimenta J, Solda R, Pereira CB. Tachycardia mediated by an AV universal (DDD) pacemaker triggered by a ventricular depolarization. *PACE*. 1986; 9: 105-107.
- [9] Sobel RM, Donaldson PR, Dhruva N. Pacemaker-mediated tachycardia: Management by pacemaker interrogation/reprogramming in the ED. *Am J Emerg Med*. 2002; 20: 336-339.

Contact

Jan C.J. Res, MD, PhD
 Zaans Medisch Centrum "De Heel"
 P.O. Box 210
 1500 EE Zaandam
 The Netherlands
 Phone: + 31 72 5817030
 Fax: + 31 72 5817031
 E-mail: janres@quicknet.nl or janres@tref.nl