

Ablation of Atrial Tachycardia and Atrial Flutter in Adults

M. ROHLA, F. GLASER, G. KRONIK

Department of Internal Medicine and Cardiology, General Hospital, Krems, Austria

Summary

Curative radiofrequency (RF) catheter ablation of drug resistant focal or reentrant atrial tachycardia and atrial flutter has been shown to be highly effective in restoring or maintaining sinus rhythm with a low incidence of complications. Between January 1995 and July 2001, the authors performed RF catheter ablation of atrial tachycardia and atrial flutter in 70 patients (24 % of all ablations performed, ectopic right atrial tachycardia in 19, sinus nodal reentrant tachycardia in three, left atrial tachycardia in one, and atrial flutter in 48 patients). The patients had been treated with different antiarrhythmic drugs that had been discontinued because of their ineffectiveness or intolerable side effects. Ectopic right atrial tachycardia was successfully treated with ablation in 15/19 (79 %) patients with a mean of 9.0 ± 2.3 RF pulses per patient (range 7 – 15, mean procedure time 123 ± 42.4 min, mean X-ray time 26 ± 8.4 min). Left atrial tachycardia was successfully ablated in a 71-year old woman (procedure time 120 min, X-ray time 32 min), but a recurrence at a new left atrial site was observed. Sinus nodal reentrant tachycardia was successfully treated with modification of the sinus node in all three patients (100 %). The RF energy was delivered in the superior region of the crista terminalis with a mean of 4.0 ± 2.0 RF pulses per patient (range 2 – 7, mean procedure time 133 ± 9 min, mean X-ray time 28 ± 9 min). Type I atrial flutter was interrupted and rendered non-inducible after a single session in 44/48 (92 %) patients. 41 (85 %) of the successfully treated patients had a bi-directional, and three patients (15 %), a uni-directional isthmus block after ablation. Acute or chronic complications were not observed. Consequently, RF catheter ablation of right-sided atrial tachycardia, sinus nodal reentrant tachycardia, and typical atrial flutter is a safe and highly effective treatment. Centers with experienced operators but a low interventional rate can also work successfully with a low risk of complications.

Key Words

Catheter ablation, atrial tachycardia, atrial flutter, mapping

Introduction

Tachycardias that arise solely within atrial tissues and are independent of atrioventricular nodal conduction are defined as atrial. If the site of origin is outside of the sinus nodal region, then the tachycardia is "ectopic." Paroxysmal tachycardias arising from the sinus nodal region have been defined as sinus nodal reentrant tachycardia. Electrocardiographically, atrial tachycardias are distinguished from atrial flutters by a slower atrial rate and the presence of an isoelectric baseline between P-waves.

Atrial tachycardias are the third most common form of supraventricular tachyarrhythmias referred for ablation.

The prevalence of atrial tachycardia shows a bimodal distribution with a higher frequency in the very young and older population [1]. Multifocal, drug-refractory atrial tachycardias can be effectively treated with atrioventricular junction modification [2,3] or atrioventricular node ablation and pacemaker implantation [4]. Curative radiofrequency (RF) catheter ablation of focal or reentrant right atrial tachycardia and atrial flutter has shown to be highly effective in restoring or maintaining sinus rhythm, in eliminating clinical symptoms and avoiding or reversing tachycardia-induced cardiomyopathy with a low incidence of complications [5,6].

Materials and Methods

Patients

Between January 1995 and July 2001, RF catheter ablation of atrial tachycardia and atrial flutter was performed in 70 patients (24 % of all ablations performed, ectopic right atrial tachycardia in 19, sinus nodal reentrant tachycardia in three, left atrial tachycardia in one, and atrial flutter in 48 patients). The patients had a mean history of arrhythmia of 6 ± 5 years. The mean age of the patients was 60 ± 10 years (range 31 – 80); 22 were women and 48 men. The patients had been treated with different antiarrhythmic drugs that were eventually discontinued because of their ineffectiveness or intolerable side effects. Structural heart disease was present in five patients (23 %) in the atrial tachycardia group, and in 28 patients (58 %) in the atrial flutter group.

Patients underwent initial evaluation that included history, physical examination, laboratory tests, ECG, 24-hour Holter monitoring (57 patients), and exercise stress testing (39 patients). Before the electrophysiologic study and ablation procedure, each patient gave their informed consent.

Electrophysiologic Study

Patients were studied in the post-absorptive state under light sedation (5 – 10 mg diazepam or midazolam, if required). Multipolar 4-, 6-, and 7-F catheters (Cordis Webster, USA, or Medtronic, USA) were inserted into the right and left femoral vein and into the right internal jugular vein for pacing, mapping and ablation, respectively. Intravenous heparin was administered as an initial dose of 5000 units at the onset of the procedure, and subsequent boluses of 1000 units/hour throughout the procedure. Surface electrocardiographic leads and endocardial electrograms were displayed and recorded simultaneously with a multichannel Siemens mingo-graph with a paper speed of 100 – 200 mm/s, using high-gain amplification (0.1 mV/cm) and a 30- to 500-Hz bandpass.

Mapping Technique

7-F quadripolar deflectable tip catheters (B-, C-, D-curve types from Cordis Webster; RF Performr, RF Conductr MC, Cosio Fluttr, all from Medtronic) were advanced into different right atrial areas. In one patient with left atrial tachycardia, a transseptal approach through the patent foramen ovale was performed.

Atrial tachycardia mapping was based on identification of the earliest bipolar atrial endocardial electrogram recorded during atrial tachycardia [7-9]. In the most cases, pace-mapping and entrainment techniques were used. In patients presenting with sustained atrial flutter, mapping proceeded immediately after positioning the catheters in the heart. In patients presenting with sinus rhythm, atrial flutter was induced by atrial programmed stimulation or burst pacing to confirm its mechanism. The diagnosis of either the common or the uncommon form of type I atrial flutter was determined by observing a counter-clockwise or clockwise activation pattern in the right atrium and around the tricuspid valve annulus, respectively [10-12]. Furthermore, the classical criteria for entrainment, including concealed entrainment during pacing from the isthmus region, showing that the reentry circuit uses the subeustachian isthmus, were confirmed.

RF Current Application

RF energy (482.6 ± 5 kHz unmodulated sine-wave output up to 50Ω into $50 - 250 \Omega$) was delivered through an RF generator (Atakr, Medtronic) with a temperature setting of 60 to 70 °C for 30 s at each point with a conventional or Cosio Fluttr ablation catheter. In all cases, a temperature-guided energy application was used. During ablation of atrial flutter, the linear lesion was made sequentially with point-by-point RF energy application (without moving the catheter during RF delivery) from the tricuspid annulus to the inferior vena cava. The end points of the ablation session were termination and non-inducibility of atrial tachycardia or atrial flutter before and during orciprenaline infusion. Additionally, in atrial flutter pace mapping was performed to determine the development of bi-directional conduction block in the sub-eustachian isthmus.

Follow-up

The patients underwent 24-h telemetry after the ablation session and pre-discharge electro- and echocardiography. In the atrial flutter group, warfarin was prescribed for the first month after ablation to reduce the risk of embolic complications in the event of recurrence of atrial flutter or atrial fibrillation. Each patient was evaluated at 1, 6, and 12 months after ablation.

Outcomes

There were four predetermined outcomes: ablation success, development of complications, arrhythmia

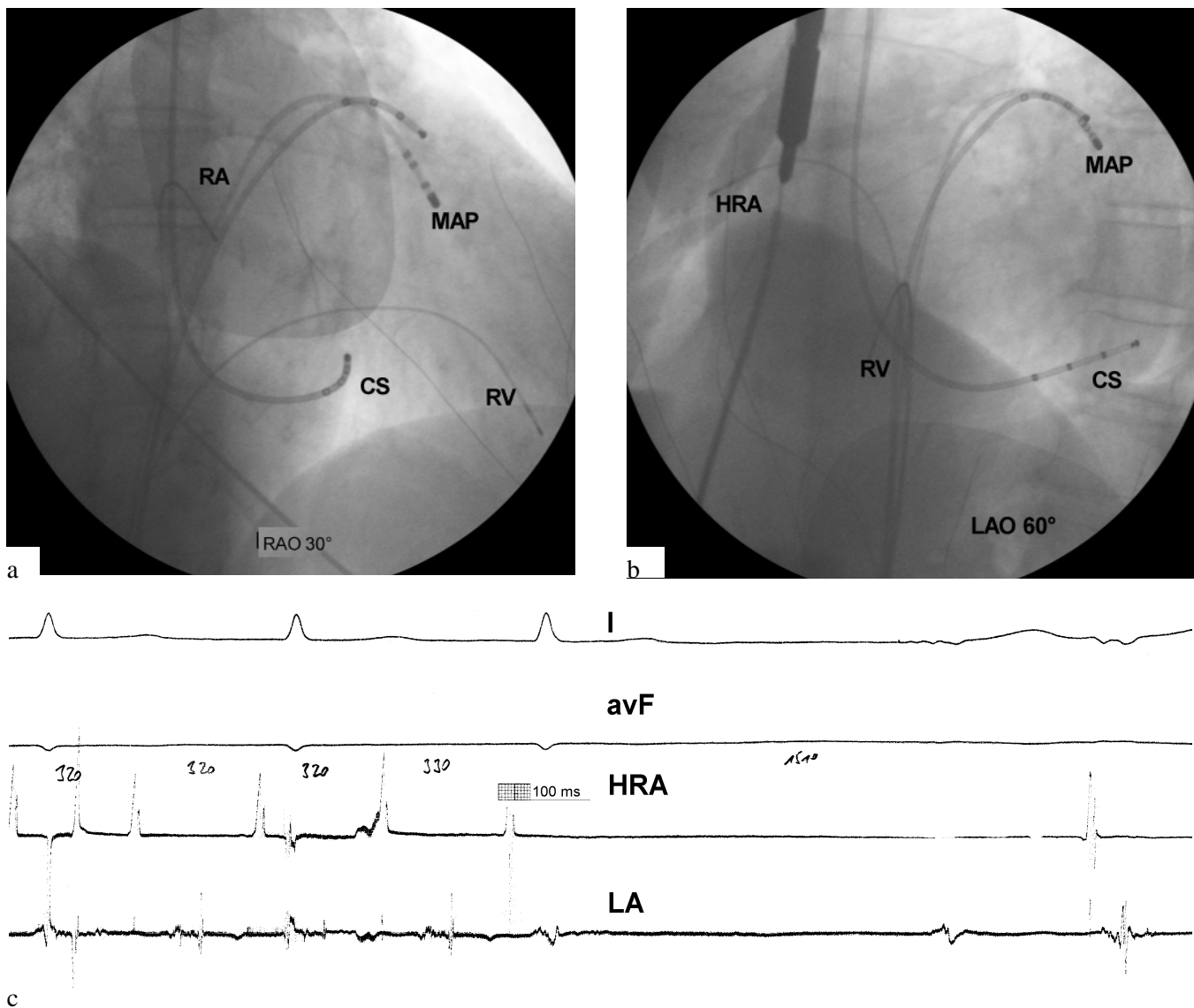


Figure 1. Mapping and ablation of left atrial tachycardia in the high anterolateral left atrium. Right anterior oblique (right anterior oblique view: RAO 30°, panel a) and left anterior oblique (left anterior oblique view 60°, panel b) fluoroscopic frames showing the location of the ablation catheter (MAP). During radiofrequency energy delivery, an abrupt termination of left atrial tachycardia after slowing was observed (panel c). RA = right atrium, RV = right ventricle, CS = coronary sinus, HRA = high right atrium, LA = left atrial reference catheter, ECG leads I and avF.

recurrence, and death. Catheter ablation procedures were classified at the completion of the procedure as acutely successful, partially successful, or unsuccessful on the basis of whether all ablation targets had been successfully eliminated. Complications were classified as major or minor. Major complications were defined as those that resulted in permanent injury or death, required an intervention for treatment, or prolonged the duration of hospitalization. With the use of long-term

follow-up data, patients were further classified as having a recurrence or not and as dead or alive.

Results

Ectopic right atrial tachycardia was successfully treated with ablation in 15/19 (79 %) patients with a mean of 9.0 ± 2.3 RF pulses per patient (range 7 – 15). The mean procedure time was 123 ± 42.4 min with a mean

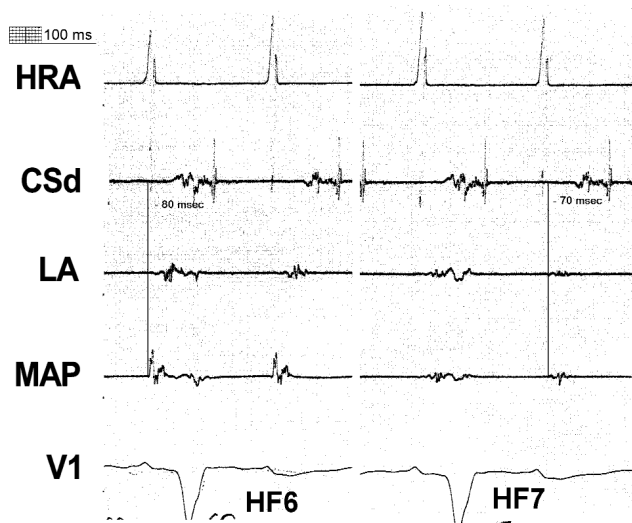


Figure 2. Local electrograms at the successful ablation site during left atrial tachycardia. The local atrial deflection (MAP) was 70 – 80 ms before the onset of the atrial signal in the distal coronary sinus electrode (CSd). Radiofrequency energy application (HF6) at this site increased the left atrial tachycardia cycle length by 20 – 30 ms followed by left atrial tachycardia termination during the next energy application (HF7). HRA = high right atrium, LA = left atrium, ECG lead V1.

X-ray time of 26 ± 8.4 min. The interval between the onset of the intracavitary atrial deflection and the onset of the right atrial tachycardia P-wave at the successful ablation site was -42 ± 9.6 ms. There were two right atrial tachycardias arising from the crista terminalis, two from the tricuspid annulus, two from the anteroseptal area, two from the basal right atrium, three from the posteroseptal area, one from the right atrial appendage, and seven from other right atrial free wall areas. Acute or chronic complications were not observed.

Left atrial tachycardia was successfully treated with ablation in a 71-year old woman. The patient had a persistent drug-refractory atrial tachycardia with a cycle length of 290 ms and 2:1 AV conduction. Symptoms of palpitations and a tachycardia-induced cardiomyopathy were documented with a markedly dilated left atrium (70 mm). The tachycardia was terminated and rendered noninducible during the seventh energy application (Figure 1c) in the high anterolateral left atrium (Figures 1a, b). At this site, a very early and markedly

fractionated local electrogram was detected (Figure 2). The procedure time was 120 min with an X-ray time of 32 min. Two months later, a drug-resistant new atrial tachycardia with a cycle length of 400 – 420 ms recurred. This tachycardia could be easily and reproducibly terminated with burst stimulation from the right atrium, but it then recurred, causing significant symptoms. The mapping revealed a new left atrial focus in the inferolateral left atrium. The ablation at this site was not successful. Therefore an ablation of the AV node with pacemaker implantation (AT 500 DDDR antiarrhythmic device, Medtronic) was performed. Acute or chronic complications were not observed.

Sinus nodal reentrant tachycardia was successfully treated with modification of the sinus node in all three patients (100 %). The RF energy was delivered in the superior region of the crista terminalis with a mean of 4.0 ± 2.0 RF pulses per patient (range 2 – 7). The mean procedure time was 133 ± 9 min with a mean X-ray time of 28 ± 9 min. An interval between the onset of the intracavitary atrial deflection and the onset of the sinus nodal reentrant tachycardia P-wave at the successful ablation site was -28 ± 9 ms. Acute or chronic complications were not observed.

Type 1 atrial flutter was interrupted and rendered non-inducible after a single session in 44/48 (92 %) patients. 41 (85 %) of the successfully treated patients had a bidirectional, and three patients (15 %) a unidirectional isthmus block after ablation. In the 12-month follow-up period, 37 out of 44 patients (84 %) were free of symptoms and had no recurrence of atrial flutter. Five patients (11 %) had recurrences of atrial flutter, and two patients had episodes of atrial fibrillation not previously documented. The mean procedure time was 133 ± 48 min with a mean X-ray time of 41 ± 23 min. Acute or chronic complications were not observed.

Discussion

RF catheter ablation of right-sided atrial tachycardia, sinus nodal reentrant tachycardia and typical atrial flutter is a safe and highly effective treatment. Centers with experienced operators but a low interventional rate can also work successfully with a low risk of complications. Left-sided atrial tachycardias are much less well known, and ablation should be performed only in centers with staff highly experienced in this technique.

References

- [1] Ko JK, Deal BJ, Strasburger JF, et al. Supraventricular tachycardia mechanisms and their age distribution in pediatric patients. *Am J Cardiol.* 1992; 69: 1028-1032.
- [2] Shah RP, Kam RM, Teo WS. Incessant ectopic atrial tachycardia and tachycardia-related cardiomyopathy: Therapeutic options and potential for cure. *Ann Acad Med Singapore.* 1999, 28: 871-874.
- [3] Ueng KC, Lee SH, Wu DJ, et al. Radiofrequency catheter modification of atrioventricular junction in patients with COPD and medically refractory multifocal atrial tachycardia. *Chest.* 2000; 117: 52-59.
- [4] Tucker KJ, Law J, Rodriques MJ. Treatment of refractory recurrent multifocal atrial tachycardia with atrioventricular junction ablation and permanent pacing. *J Invasive Cardiol.* 1995; 7: 207-212.
- [5] Lopez Gil M, Arribas F, Cosio FG. Radiofrequency ablation of atrial tachycardia and atrial flutter. *Z Kardiol.* 2000; 89 (Suppl 3):144-152.
- [6] Anguera I, Brugada J, Roba M, et al. Outcomes after radiofrequency catheter ablation of atrial tachycardia. *Am J Cardiol.* 2001; 87: 886-890.
- [7] Chen S-a, Chiang C-E, Yang C-J, et al. Radiofrequency catheter ablation of sustained intra-atrial reentrant tachycardia in adult patients: Identification of electrophysiological characteristics and endocardial mapping techniques. *Circulation.* 1993; 88: 578-587.
- [8] Weiss C, Willems S, Cappato R, et al. High frequency current ablation of ectopic atrial tachycardia. Different mapping strategies for localisation of right- and left-sided origin. *Herz.* 1998; 23: 269-279.
- [9] Sanders WE Jr, Sorrentino RA, Greenfield RA, et al. Catheter ablation of sinoatrial reentrant tachycardia. *J Am Coll Cardiol.* 1994; 23: 926-934.
- [10] Cosio FG, Lopez-Gil M, Goicolea A, et al. Radiofrequency ablation of the inferior vena cava-tricuspid valve isthmus in common atrial flutter. *Am J Cardiol.* 1993; 71: 705-709.
- [11] Fischer B, Haissaguerre M, Garrigues S, et al. Radiofrequency catheter ablation of atrial flutter in 80 patients. *J Am Coll Cardiol.* 1995; 25: 1365-1372.
- [12] Chen SA, Chiang CE, Wu TJ, et al. Radiofrequency catheter ablation of common atrial flutter: Comparison of electrophysiologically guided focal ablation technique and linear ablation technique. *J Am Coll Cardiol.* 1996; 27: 860-868.

Contact

M. Rohla, MD
Abteilung für Innere Medizin und Kardiologie
Krankenhaus Krems an der Donau
Mitterweg 10
A-3500 Krems
Austria
Telephone: +43 2732 804
Fax: +43 2732 804 702
E-mail: m12rohla@aon.at