

Successful Prevention of Atrial Flutter Using Atrial Pacing and an Initially High Threshold in a Young Patient with Partial Atrial Standstill – A Case Report

J.C.J. RES, G. KROON
De Heel, Zaans Medical Center, Zaandam, The Netherlands

A. MEIJER, B. VAN GELDER
Catherina Hospital, Eindhoven, The Netherlands

Summary

This case report describes a young patient with paroxysmal atrial flutter and partial atrial standstill. At very young age, he was symptomatic for dizziness, fatigue, and fast palpitations. The first (AAIR) pacemaker was implanted at the age of 8 years due to sick sinus syndrome. Three years later an exit block with pauses up to 3.8 seconds necessitated a revision of the atrial pacemaker system. Due to the inability to pace the right atrial appendage with normal outputs, a new VVIR system was implanted. During follow-up it was apparent that the patient was severely symptomatic of paroxysmal episodes of atrial flutter despite high doses of either propafenone or sotalol. Radiofrequency ablation of the atrial flutter was not feasible because of the inability to check isthmus block. The VVIR pacemaker was upgraded to a DDD model in order to prevent the recurrence of atrial flutter. The tip of the atrial lead was positioned at the right lateral free wall because capture was only achieved at that site and initially at very high outputs (10 V and 1 ms). However, after 10 minutes of permanent pacing, the atrial output could be lowered to normal values and pacing was successfully performed for over one year at standard output settings. Furthermore, the atrial flutter was completely suppressed through DDD pacing.

Key Words

Pacing threshold, atrial standstill, atrial flutter, preventive pacing

Introduction

Atrial standstill is a long known phenomenon. It has been described in animal experiments as a temporary cessation of atrial activity using a toxic dose of digitalis with or without quinidine. This first study was already published in 1897 [1]. Experiments with humans were first reported in 1913 and 1916 by Lewis and White, respectively [2,3]. Atrial standstill, which is also called silent atrium or atrial quiescence, is defined as a lack of atrial activity that is documented by electrocardiographic, cineangiographic, or echocardiographic criteria. This means that a P-wave is visible neither on the surface ECG nor on intra-atrial recordings, and there is complete refractoriness for electrical stimulation in the right and left atrium. Mechanical

activity or atrial contraction is also absent. Different subpatterns of atrial standstill have been outlined, such as partial standstill versus total standstill and chronic standstill versus temporary standstill [4,5]. Several temporary cases have been reported, such as hyperkalemia, drug intoxication, post myocarditis, as well as conditions during the convalescence phase following open heart operations. Chronic atrial standstill has been described as idiopathic in relation to familial (amyloidosis) standstill or in association with muscular dystrophy and cardiomyopathy.

To diagnose total atrial standstill, a complete mapping study of both atria is required. On the other hand, partial atrial standstill may require high output, to pace the

atrium [6]. In addition, partial atrial standstill can be associated with atrial arrhythmias [5,7].

In this case report we describe a patient with atrial standstill and intermittent atrial flutter. We observed that part of the atrium could be paced with initially high output before capture and in combination with a prolonged HV-interval. The pacing threshold decreased dramatically to normal values after a period of pacing. Furthermore, during long-term follow-up the recurrence of the atrial flutter disappeared.

Case Presentation

An 8-year-old boy with symptomatic sick sinus syndrome was referred to the pacemaker clinic. In the presence of normal atrio-ventricular conduction, an atrial pacemaker was implanted with an endocardial lead, which was tunneled to the abdominally positioned AAIR pacemaker. The tip of the endocardial lead was positioned in the right atrial appendage. The threshold was 1.2 V at 0.5 ms, the lead impedance 417 Ω , and the P-wave 2.5 mV. After 3 years of follow-up, the patient became symptomatic as a result of a lead fracture that occurred while taking Karate lessons. The unipolar lead was repaired and the threshold and

P-wave amplitudes were not changed. Three years later an exit block with pauses up to 3.8 seconds necessitated a revision of the atrial pacemaker system. Due to the inability to pace the right atrial appendage with normal outputs, a new VVIR system was implanted. Two years later, the patient experienced a severe trauma precisely in the area of the pulse generator, which caused an infection in the pacemaker pocket. The ventricular pacemaker and the two leads were explanted successfully. A new VVIR system with a tined lead was implanted at the contra lateral side because an attempt to stimulate the right atrial appendage had failed. During follow-up it was apparent that the patient was severely symptomatic of paroxysmal episodes of atrial flutter despite high doses of either propafenone or sotalol (Figure 1). The recurrent atrial flutter persisted for 2 – 3 days and decreased the patient's exercise tolerance and concentration. Therefore, the patient was referred for radiofrequency ablation of the atrial flutter, which was impossible because the isthmus block could not be tested due to the inability to pace the right atrium at several places. However, during this procedure sporadic, spontaneous, atrial activation and capture at the right lateral site was noticed. Additional measurements were an HV-inter-

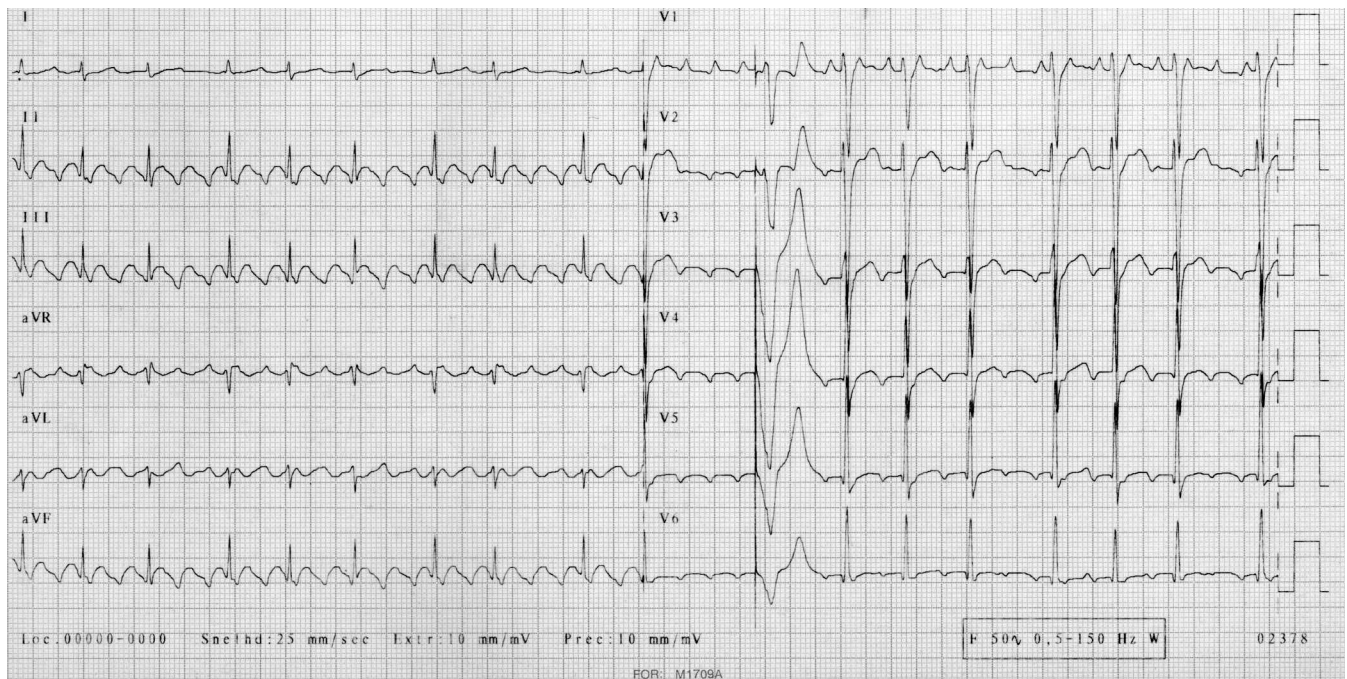


Figure 1. Atrial flutter with variable AV conduction and intermittent ventricular pacing: The DDDR pacemaker is operating in the VVIR pacing mode due to the mode switch (lower rate is 70 beats/min).

val of 120 ms and a Wenckebach point at 420 ms. It was suggested that permanent atrial stimulation from the right lateral wall would be hemodynamically favorable and could diminish the recurrence of atrial flutter. Therefore, a DDD pacemaker was implanted, together with an atrial screw-in lead. At several positions at the right atrial wall, no intracardiac atrial signal could be recorded, and the atrium could not be stimulated with an output of 10 V at 1 ms. At the mid-lateral free wall of the right atrium, stimulation was successful with an output just below 10 V and 1 ms (Figures 2 and 3). After waiting 10 minutes, the threshold was decreased to 1.5 V at 0.5 ms. Lead impedance was 670 Ω. Follow-up the next day revealed a similar pacing threshold between 1.0 and 1.5 V at 1.0 ms. The patient has been monitored for over a year. During this time the pacemaker has functioned well with an atrial output of 5.0 V (atrial threshold of 1.0 V), and the palpitations

has been eliminated. The Holter function of the pacemaker did not disclose high atrial rates. An echocardiographic evaluation showed either minimal or no contraction of the atrial walls.

Discussion

Atrial flutter and fibrillation can be prevented through atrial stimulation [8]. However, this is not proven in the presence of partial atrial standstill in a larger series. In our patient, pacing in the atrium improved his clinical condition and eliminated any recurrence of atrial flutter. The combination of atrial standstill and atrial arrhythmias is not a rare phenomenon [5,9-13]. It has been discussed whether the sinus node itself is involved in the disease or the surrounding tissue in the atrium around the sinus node is diseased. Pathologically, the inexcitability of the atrium even at

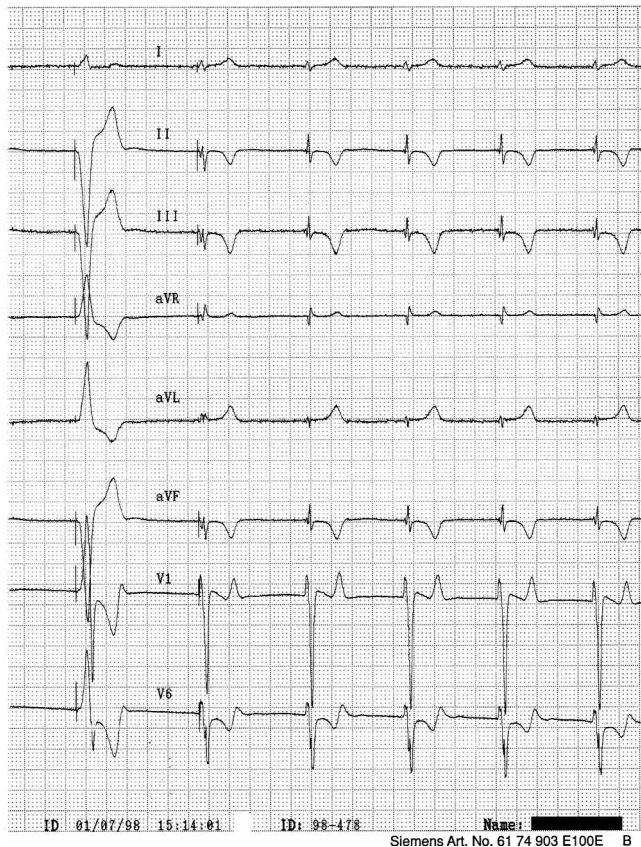


Figure 2. Ventricular pacing and spontaneous, junctional rhythm is present in the absence of atrial activity.

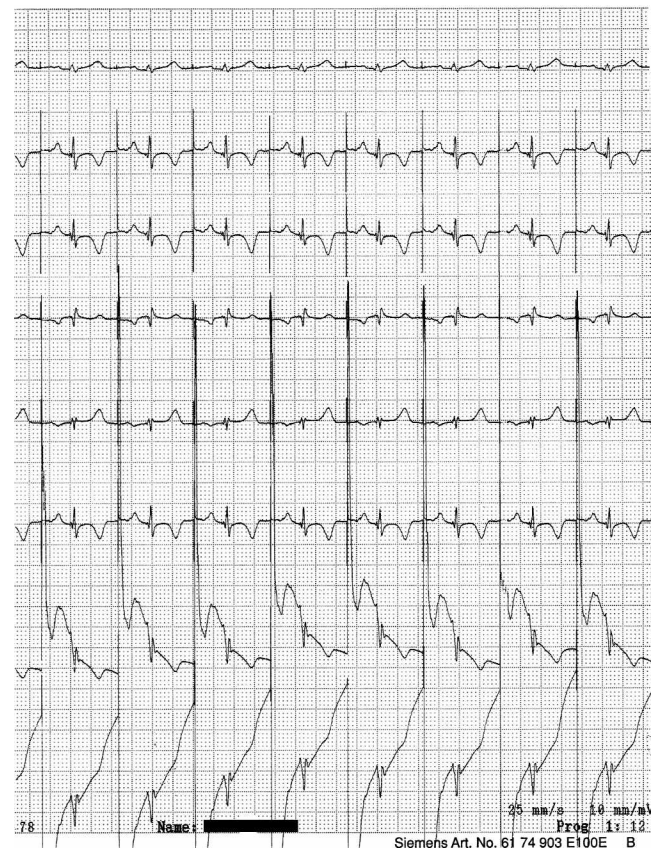


Figure 3. After implantation of the screw-in lead, atrial capture was achieved. The lower two recordings are from the distal and proximal pacing electrode during pacing. Note the long interval between the stimulus artefacts and atrial activity.

high output energy suggests a disruption of the atrial myocardium, which is then replaced by inexcitable fibrous tissue, fibro-fatty tissue, or amyloid. The literature shows conflicting reports. In two reports, histologic damage of the sinus node has been demonstrated [14,15], and two other reports show no histologic damage of the sinus node itself [16,17]. However, in one case, chronic active myocarditis was extensive in a dog that presented with atrial standstill, myocarditis, and conduction block [18]. The pathology revealed extensive lesions by gross examination, and microscopic findings showed active chronic myocarditis (50 to 60 % of all tissue). The coronary arteries were normal.

Permanent atrial standstill has been described in many publications since it was recognized in humans. In most of the patients, a cardiomyopathy, whether ischemic in origin or not, is the underlying disease, but in a few reports myocarditis has been diagnosed [19-21]. In our patient, a myocarditis at such an early age may be the most likely cause of the atrial standstill. The rest of the patient's family remained unaffected. However, familial forms of the condition have been described on several occasions [7,9,13,22-24].

Many recognize that pacemaker implantation may improve the exercise tolerance in patients with an atrial standstill. Slow junctional rhythms that result from a lack of any atrial activity may limit the patient's exercise tolerance and lead secondarily to dilatation of the left ventricle. The symptoms may improve after implantation of a rate-responsive ventricular pacemaker [25]. In our patient, the upgrade from VVIR pacing to DDDR pacing was attempted in the hope that the paroxysms of atrial flutter would decrease or stop altogether. After more than one year of follow-up, the patient had no recurrence of atrial flutter, which was confirmed by the pacemaker telemetry diagnostics.

The combination of atrial standstill with symptomatic conduction block is seldom reported [26,27], although atrial fibrillation or flutter with a slow ventricular rate is documented in a few reports [6,9,11-13,28]. Therefore, atrial disease is not restricted to the atrium. In the patient we studied, a Wenckebach point was found at a 420 ms pacing interval, but the HV-interval was severely prolonged with 120 ms as a sign of conduction system disease. The patient still had high ventricular rates during exercise when the atrial flutter was present. Without medication, the atrial flutter was conducted to the ventricles at a rate of 150 beats/min or even higher during exercise.

Temporary atrial standstill can be explained by a different functional state of the atrial myocardium: a hypopolarization of the cellular membrane. This temporary form can be caused by medication [29-30] or by hyperkalemia [31]. In the case of a partial standstill or an atrial standstill in combination with fibrillation or flutter, it is possible to excite the atrium in large areas. Because of the initial high output needed for atrial capture, it can be postulated that the prolonged period of atrial quiescence itself induces a hypopolarization of the membrane. It is not clear how and under what conditions an arrhythmia will start. As soon as the atrial myocardium is captured by a stimulus, the hypopolarization may be diminished and, thus, the next depolarization will be facilitated. In pacing terms, there is a reduction in the stimulation threshold. Once capture is achieved, prolonged periods of atrial standstill will be suppressed. Experimental data on threshold behavior at very low rates below the physiologic range are lacking. Lévy et al. [6] reported that high output pacing is required for capturing the atrium in patients with partial atrial standstill. On the other hand, the effect of the pacing rate on the threshold has only been evaluated at normal and very high rates up to 300 beats/min [32]. A decrease of the pacing threshold was described in the physiologic range over a 30-minute interval after implantation of the lead, starting from 0.84 ± 0.17 V, which is a very different situation from this case [33]. Part of the decrease may be attributed to the recovery of the electrolyte imbalance caused by active fixation. However, the real cause of the initially high pacing thresholds may be attributed either to severe hypopolarization, the mere absence of atrial myocytes, or a combination of the two.

In this case, implantation of an atrial lead and subsequent pacing was successful. The patient was taken off anti-arrhythmic drugs, and acetyl-salicylic acid was prescribed to prevent thromboembolism because mechanical atrial standstill in the absence of atrial fibrillation presents a risk of thrombi; this is certainly the case when it is associated with spontaneous contrast on the echocardiogram [14,34].

References

- [1] Cushny AR. On the action of substances of the digitalis series on the circulation in mammals. *J Exp Med.* 1897; 2: 233-299.
- [2] Lewis T. Exceptional types of slow heart action. *Quart J Med.* 1913; 6: 223.

- [3] White PD. Auricular standstill: An unusual effect of digitalis on the heart. *Boston Med Surg.* 1916; 175: 233.
- [4] Nakazato Y, Nakata Y, Hisaoka T, et al. Clinical and electrophysiological characteristics of atrial standstill. *PACE.* 1995; 18: 1244-1254.
- [5] Pop T, Treese N, Meyer J. Das elektrokardiographische Bild des Vorhofstillstandes. *Z Kardiol.* 1987; 76: 159-166.
- [6] Lévy S, Pouget B, Bemurat M, et al. Partial atrial electrical standstill: Report of three cases and review of clinical and electrophysiological features. *Eur Heart J.* 1980; 1: 107-116.
- [7] Balaji S, Till J, Shinebourne EA. Familial atrial standstill with coexistent atrial flutter. *PACE.* 1998; 21: 1841-1842.
- [8] Saksena S, Prakash A, Hill M, et al. Prevention of recurrent atrial fibrillation with chronic dual-site right atrial pacing. *J Am Coll Cardiol.* 1996; 28: 687-694.
- [9] Disertori M, Guarnerio M, Vergara G, et al. Familial endemic persistent atrial standstill in a small mountain community: Review of eight cases. *Eur Heart J.* 1983. 4: 354-361.
- [10] Harley A. Persistent right atrial standstill. *Br Heart J.* 1976; 38: 646-649.
- [11] Froment R, Touboul P, Gallavardin L, et al. Signification de la réduction spontanée de fibrillation auriculaire anciennes. *Arch Mal Coeur.* 1976; 69: 315-320.
- [12] Slama R, Coumel Ph, Perrault MA, et al. Dilatation idiopathique droite avec trouble de rythme auriculaire et paralysie auriculaire apparante. *Arch Mal Coeur Vaiss.* 1973; 66: 35.
- [13] Stables RH, Bailey C, Ormerod OJM. Idiopathic familial atrial cardiomyopathy with diffuse conduction block. *Quart J Med.* 1989; 71: 325-332.
- [14] Chavez I, Brumlik J, Sodi-Pallares D. Sobre un caso extraordinario de parálisis auricular permanente con degeneración del undulo de Keith Y Flock. *Arch Inst Cardiol Mex.* 1946; 16: 159-181.
- [15] Rosen KM, Shahbuden RH, Gunnar RM, et al. Transient and persistent atrial standstill with His bundle lesions. Electrophysiologic and pathologic correlations. *Circulation.* 1971; 44: 220-236.
- [16] Raynaud R, Jobard P, Brochier M, et al. Chronic atrial paralysis and papyraceous atrium. *Ann Cardiol Angeiol (Paris).* 1968; 17: 117-124.
- [17] James TN, Puech P. De Subitaneis morbitus XI. Type A Wolff-Parkinson-White syndrome. *Circulation.* 1974; 50: 1264-1280.
- [18] Jeraj K, Ogburn PN, Edwards WD, et al. Atrial standstill, myocarditis and destruction of cardiac conduction system: Clinicopathologic correlation in a dog. *Am Heart J.* 1980; 99: 185-192.
- [19] Wohlgelernter D, Otis CN, Batsford WP, et al. Myocarditis presenting with "silent" atrium and left atrial thrombus. *Am Heart J.* 1984; 108: 1557-1558.
- [20] Straumanis JP, Wiles HB, Case CL. Resolution of atrial standstill in a child with myocarditis. *PACE.* 1993; 16: 2196-2201.
- [21] Talwar KK, Dev V, Chopra P, et al. Persistent atrial standstill - Clinical, electrophysiological, and morphological study. *PACE.* 1991; 14: 1274-1280.
- [22] Shah MK, Subramanyan R, Tharakan J, et al. Familial total atrial standstill. *Am Heart J.* 1992; 123: 1379-1382.
- [23] Allensworth DC, Rice GJ, Lowe GW. Persistent atrial standstill in a family with myocardial disease. *Am J Med.* 1969; 47: 775-784.
- [24] Surawicz B, Hariman RJ. Follow-up of the family with congenital absence of sinus rhythm. *Am J Cardiol.* 1988; 61: 467-469.
- [25] Solti F, Rény-Vámos F, Gyöngi T. Atrial standstill: an indication for rate responsive pacing. *PACE.* 1990; 13: 830-832.
- [26] Amram SS, Vagueiro C, Pimenta A, et al. Persistent atrial standstill with atrial inexcitability. *PACE.* 1978; 1: 80-89.
- [27] Cardenas M, Gonzalez Hermosillo A, et al. Estudios electrofisiológicos en la parálisis auricular permanente. *Arch Inst Cardiol Mex.* 1977; 47: 691-697.
- [28] Assmann I, Oltmanns G, Dittrich P, et al. Electrophysiological findings in atrial arrest. *Z Gesamte Inn Med.* 1980; 35: 382-387.
- [29] Ruff P, Leier CV, Schaal SF. Temporary atrial standstill. *Am Heart J.* 1979; 98: 413-420.
- [30] Tognarini S, Pardini E. A case of atrial paralysis during the use of intravenous flecainide acetate. *Cardiologia.* 1989; 34: 725-729.
- [31] Fauchier JP, Cosnay P, Latour F. The heart and hyperkalemia. *Arch Mal Coeur Vaiss.* 1984; 77 (Spec No): 23-33.
- [32] Kay GN, Mulholland DH, Epstein AE, et al. Effect of pacing rate on the human atrial strength-duration curve. *J Am Coll Cardiol.* 1990; 15: 1618-1623.
- [33] De Buitelir M, Kou WH, Schmaltz S, et al. Acute changes in pacing threshold and R- or P-wave amplitude during permanent pacemaker implantation. *Am J Cardiol.* 1990; 65: 999-1003.
- [34] Koller-Strametz J, Wieselthaler G, Kratochwill C, et al. Thromboembolism associated with junctional escape rhythm and atrial standstill after orthotopic heart transplantation. *J Heart Lung Transplant.* 1995; 14: 999-1002.

Contact

Dr. J.C.J. Res
 "De Heel" Zaans Medisch Centrum
 PO Box 210
 1500 EE Zaandam
 The Netherlands
 Telephone: + 31 72 5817030
 Fax: + 31 72 5817031
 E-mail: janres@tref.nl