

Reduction of Mitral Regurgitation by Endocardial Right Ventricular Bifocal Pacing in Cases of Dilated Cardiomyopathy

J. C. PACHON M., R. N. ALBORNOZ, E. I. PACHON M., V. M. GIMENES, J. PACHON M., M. Z. C. PACHON, P. T. J. MEDEIROS, E. A. RAMOS F., J. E. M. R. SOUSA, A. D. JATENE
Dante Pazzanese Cardiology Institute and Sao Paulo Heart Hospital, Sao Paulo, Brazil

Summary

The QRS widening caused by conventional pacing impairs systolic, diastolic, and mitral function. All of these may be improved by left-ventricular or biventricular pacing. However, the left-ventricular access is a barrier not present in the right-ventricular bifocal pacing that we have proposed. In atrial fibrillation, by connecting the patient's atrial channel to a septal subpulmonary lead and the ventricular channel to a conventional apical lead, we can obtain bifocal pacing by programming the pacemaker AV-interval at near to 0. It is thus easy to compare the QRS duration, the echocardiographic mitral regurgitation, and the left atrial area in the same patient for septal, conventional, or bifocal pacing by programming different configurations. In comparison to conventional or septal pacing bifocal pacing was shown in 21 patients to cause advancement and shortening of systole, a reduction in the mitral regurgitation time, better synchronization in papillary muscle activation, and a prolonged diastole. These results clearly demonstrate the superior performance of bifocal pacing. We conclude that in dilated cardiomyopathy with conventional pacing and functional mitral regurgitation, the endocardial right-ventricular bifocal pacing provides an acute and significant reduction in mitral regurgitation.

Key Words

Mitral regurgitation, right-ventricular bifocal pacing, left atrial area

Introduction

Functional mitral regurgitation is very common in patients with severe dilated cardiomyopathy, mainly when there is a wide QRS due to left bundle block [1] or chronic conventional endocardial pacing [2,3]. The consensus is that this dysfunction is worsened by the inotropic asynchrony caused by monofocal ectopic ventricular activation.

Several reports have shown the advantages of left-ventricular or biventricular pacing [4,5-7]. However, the inherent difficulties related to left-ventricular access make this pacing mode unsuitable in some cases.

Three years ago, we proposed endocardial right-ventricular bifocal pacing in order to reduce QRS duration [8] by improving the left-ventricular inotropic synchrony in pacemaker patients or in patients with complete left bundle branch block. Since then, we have remarked that this pacing mode decreases functional mitral regurgitation.

The objective of this study is to compare, in the same patient, the effects on functional mitral regurgitation of conventional endocardial monofocal ventricular pacing and bifocal endocardial right-ventricular pacing in cases of severe dilated cardiomyopathy and with permanent pacemaker indication.

Patients

Twenty-one patients were included, 14 male and 7 female, with aged 37 to 82 years (mean 62.8 ± 12.4), all with severe dilated cardiomyopathy, functional mitral regurgitation, and pacemaker indication due to atrial fibrillation with total or advanced AV block (15 patients) or due to sinus rhythm plus total AV block (5 patients). The mean NYHA functional class was 3.1 ± 0.8 . The etiologies were Chagas' disease in 11 patients, total AV-block after AV-node ablation for

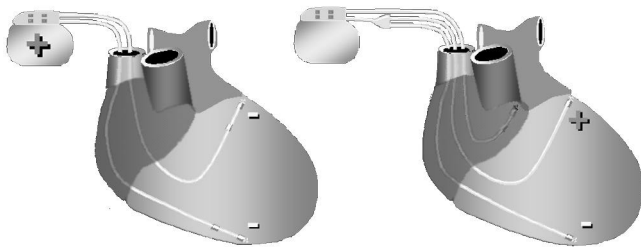


Figure 1. Scheme of the lead position and pacemaker connections in patients with and without atrial fibrillation. See text for details.

tachycardiomyopathy in 3, chronic ischemic cardiomyopathy in 4, and undetermined in 3. Four patients had definitive pacemakers with elective indication to change the generator due to battery depletion.

Methods

All patients underwent pacemaker implantation with 2 endocardial right-ventricular leads, the first one placed in the septal subpulmonary area (active fixation) and the second one conventionally, in the apex of the right ventricle (passive or active fixation). In the 6 patients without atrial fibrillation, an active fixation atrial lead was also implanted according to the

conventional endocardial technique. The pacemakers were all DDD: Biotronik Dromos (9 patients), Biotronik Actros (6 patients), CPI Discovery (3 patients), CPI Pulsar (3 patients). In 16 patients with atrial fibrillation, the pacemakers were connected as follow: the atrial channel was connected to the septal lead and the ventricular channel was connected to the lead implanted in the right-ventricular apex. (Figure 1) The pacemakers were previously programmed to DDT, DVI or DDD mode at AV intervals of 10 or 15 ms.

The connections of the pacemakers in 5 patients with sinus rhythm were as follows: The atrial channel was connected to the atrial lead. With help of one "Y" connector, the positive pole of the ventricular channel was connected to the tip of the septal lead and the negative pole was connected to the tip of the right-ventricular apex lead (Figure 1). The pacemakers were programmed in DDD mode with AV interval optimized according to the clinical features.

All patients were studied with bidimensional echo-Doppler cardiogram 3 ± 0.9 weeks after surgery in comparing the mitral regurgitation area and the left atrium area between conventional, septal, and bifocal pacing (atrial fibrillation patients), as well as between DDD-mode apical pacing and DDD-mode bifocal ventricular pacing (sinus rhythm patients). All the usual systolic and diastolic parameters are also compared.

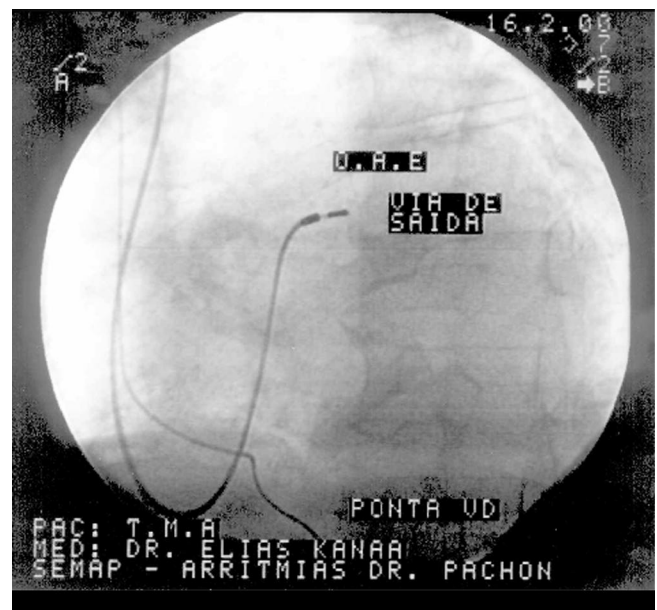
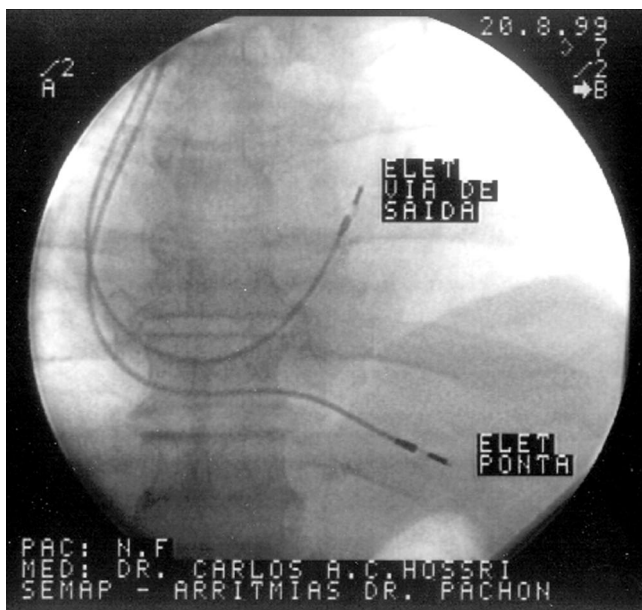


Figure 2. Radiological study in ventricular endocardial right bifocal pacing. The left anterior oblique position is very important to show the tip of the septal lead targeted toward the spinal column.

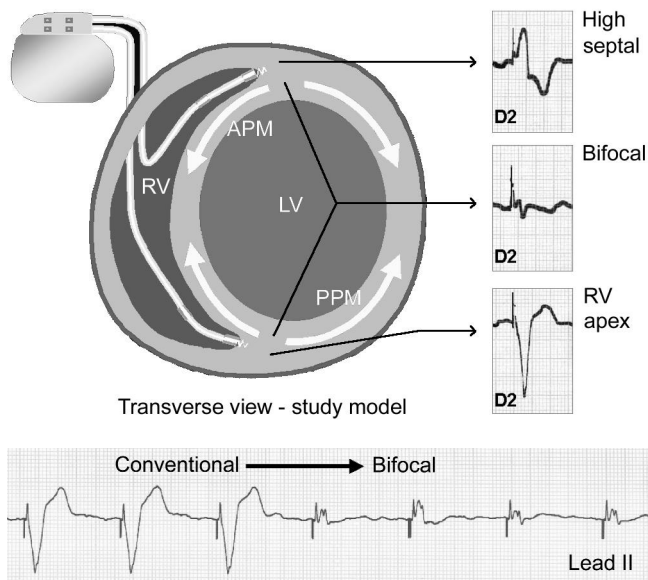


Figure 3. Scheme of the study model showing the septal and apical pacing points. The lead placement must be done in order to get the largest left ventricular portion between them. The bifocal pacing results in the shortest QRS.

Implantation Technique

The implantations were made following the classic method for endocardial bicameral pacemakers; 2 or 3 leads through the venous route was therefore easily reproducible. The first lead was positioned in the septal sub-pulmonary region (Figure 2 and Figure 3). This position was easily obtained by entering the pulmonary artery and slowly withdrawing the lead, which was previously connected to the pacemaker, up to the point at which ventricular capture could be obtained. An X-ray left-anterior oblique position was taken in order to help advance the tip of the lead as near as possible to the left ventricle (Figure 2). Bipolar active-fixation leads were used in all cases. The second lead was positioned preferably in the apex of the right ventricle (the farthest possible point from the base). Bipolar, active-fixation, atrial leads were implanted using conventional techniques. The P- and R-waves, impedance, and thresholds were obtained using regular procedures. Programming the Pacemaker during Echocardiography In the patients with atrial fibrillation, it was possible to compare three different ventricular pacing modes:

- Programming the DDD pacemaker to the conventional VVI mode, we obtained classic VVI pacing (apical ventricular unifocal pacing).

- Programming the DDD pacemaker to the conventional AAI mode, we obtained ventricular septal unifocal pacing (VVI septal).
- Programming the DDD pacemaker to conventional DDD mode with AV interval of 15 or 10 ms, we obtained the VVI bifocal pacing mode (Figure 3). In those 5 sinus rhythm patients, only two ventricular pacing modes were compared:
 - The DDD mode with bifocal ventricular pacing, with the pacemaker programmed to classic DDD mode with ventricular bipolar pacing, and
 - The DDD mode with conventional unifocal ventricular pacing, with the pacemaker programmed to classic DDD mode with unipolar pacing in the ventricle.

Results

The mitral regurgitation in unifocal apical ventricular pacing (conventional pacing) was $11.9 \pm 8.5 \text{ cm}^2$. In ventricular bifocal pacing, it was $8.5 \pm 7.1 \text{ cm}^2$ ($p = 0.0005$), causing a reduction of the left atrial area from $31.0 \pm 11.2 \text{ cm}^2$ to $27.9 \pm 11.6 \text{ cm}^2$ ($p = 0.01$). In patients who also made it possible to compare the septal unifocal ventricular pacing (atrial fibrillation patients), a mitral regurgitation area of $11.0 \pm 8.4 \text{ cm}^2$ and a left atrial area of $28.8 \pm 12.9 \text{ cm}^2$ were found. The comparison of these data with classic VVI pacing showed a statistically significant reduction of the mitral regurgitation and of the left atrial area ($p = 0.03$). The mean QRS duration in 3 simultaneous leads DI, DII and DIII was $210 \pm 19.5 \text{ ms}$ in the unifocal apical pacing (conventional), $188 \pm 14.9 \text{ ms}$ in the unifocal septal pacing and $158.8 \pm 19.4 \text{ ms}$ in the right ventricular bifocal pacing (Table 1). The reduction in the QRS duration was significant in bifocal pacing ($p < 0.0001$) (Figure 3). However, the reduction in the QRS duration obtained in unifocal right septal pacing was not statistically significant ($p = 0.06$).

	QRS (ms)	MR (cm ²)	LAA (cm ²)
Septal	188.0 ± 14.9	11.0 ± 8.4	28.8 ± 12.9
Conventional	210.0 ± 19.5	11.9 ± 8.5	31.0 ± 11.2
Bifocal	158.8 ± 19.4	8.5 ± 7.1	27.9 ± 11.6

Table 1. Mean and SD of the QRS duration, mitral regurgitation area (MR) and left-atrial area (LAA) for 21 patients in conventional septal and bifocal pacing ($p < 0.05$).

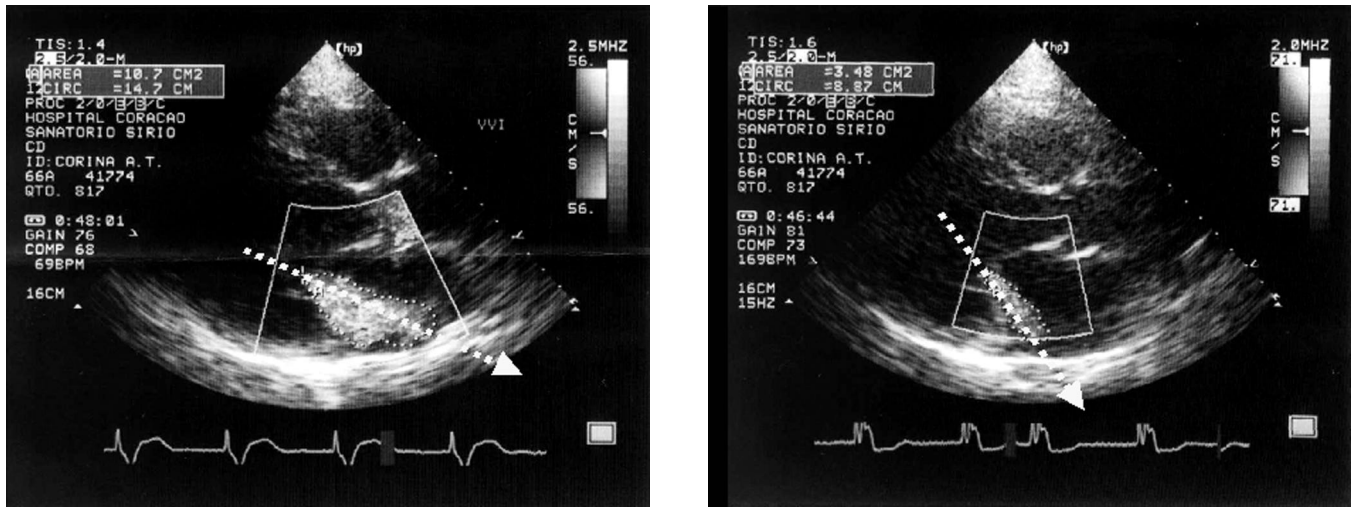


Figure 4. Echocardiographic study switching from conventional to bifocal pacing. There is a clear reduction in the regurgitation area and a change in the direction of the main regurgitation flow. Note that the QRS complex became positive in lead II.

Discussion

The ventricular pacing with wide QRS causes an important inotropic asynchrony among the ventricular cells. It prolongs the systole and the isometric contraction phase, which extends the mitral regurgitation time. Besides, a wide QRS reduces the diastolic efficiency, shortening its duration and reducing the speed of fast filling. In this way, there is an additional exacerbation of the deleterious effect to the pulmonary venous system caused by mitral regurgitation. These factors may

contribute to the development of pulmonary hypertension and heart failure. Since Furman created endocardial pacing in 1958, there has been a great expansion of the pacing indications [9,10]. However, almost nothing was done with regard to obtaining pacing with a narrower QRS. On the other hand, case reports relating the emergence of serious mitral regurgitation following unifocal conventional cardiac pacing have appeared frequently [3].

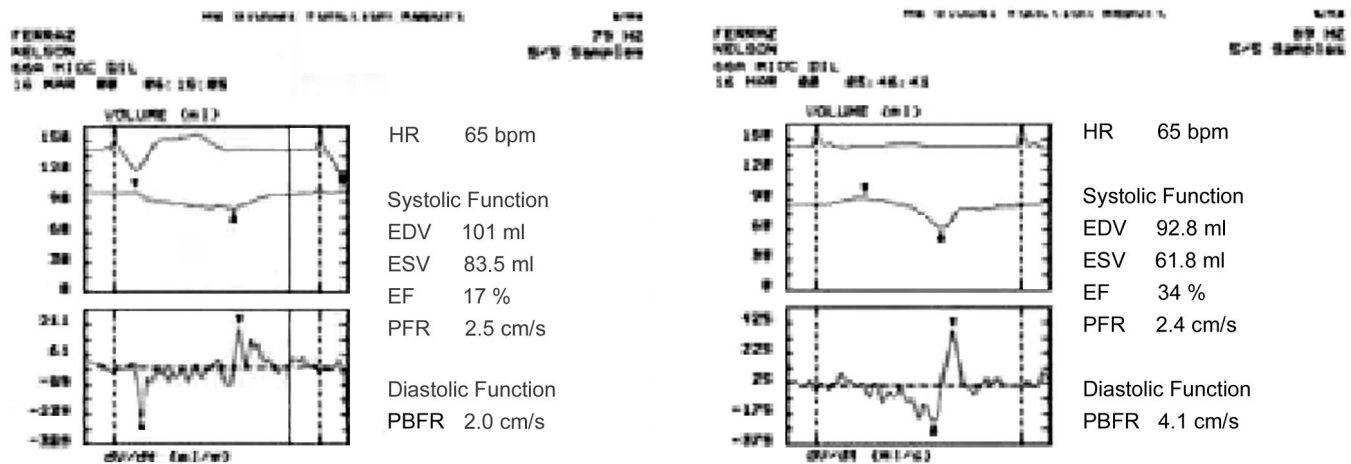


Figure 5. Echocardiographic print-out of a study in a patient paced over 6 months with bifocal pacing. It is clearly an important increase in mitral regurgitation and in cardiac volumes and an important decrease in ejection fraction and in peak fill-rate programming from bifocal to conventional.

In this report, our observations were facilitated by the study model allowing us to change the pacing points via non-invasive programming in the same session without changing the patient's position (Figure 5). In addition, this method allows each patient to act as his or her own control. Using a different method, it would be very difficult to compare small variations of mitral regurgitation between different patient groups.

We have verified that simultaneous pacing of 2 distant points in the right ventricle provides an evident reduction in the QRS duration followed by a reduction in the mitral regurgitation [8]. We believe that this highly desirable phenomenon is due to a more physiologic activation of the mitral papillary muscles (Figure 6). This seems to be confirmed by the change in the direction of the regurgitation flow when we switch between the conventional and bifocal pacing modes (Figure 4 and Figure 6). This behavior may be due to differing apposition of the mitral leaflets. We believe that septal pacing at two points nearly at the same time is more physiologic because it makes the septum stiffer at the beginning of the systole, providing better anchorage for the contraction of the remaining left-ventricular muscle. Also, by pacing the basal septum prematurely, we can obtain a predominantly positive QRS in lead II, a situation that seems to have good hemodynamic effect (Figure 7). For some patients, due to a certain delay in the septal activation, we programmed a larger "V-V" interval here (20, 30 and rarely 50 ms) in order to achieve a delay in the apical activation. In this way, we can control the positive-QRS phase in lead II. The septal subpulmonary lead

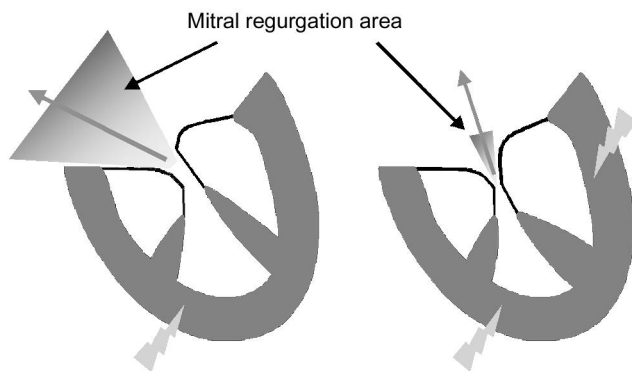


Figure 6. Scheme of the change in papillary muscle activation. With bifocal pacing, it is possible to attain greater physiologic activation of the papillary muscles, providing better mitral leaflet apposition.

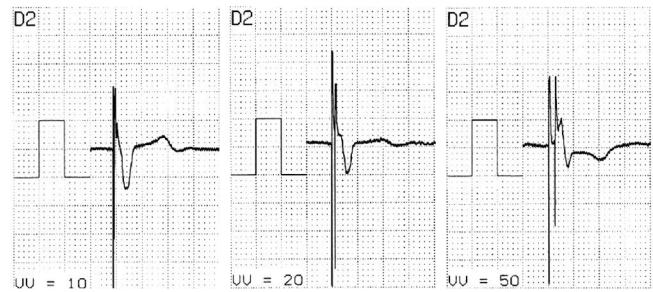


Figure 7. In patients with atrial fibrillation, having both DDD pacemaker leads implanted in the right ventricle, programming the pacemaker AV-delay results in a change in the V-V interval. With his procedure, it became possible to turn the QRS positive or negative in lead II, allowing the septum activation to change direction completely in order to choose the best mitral performance via echocardiogram. For cases without atrial fibrillation, an "A-V-V" pacemaker will need to be possible within this range of resources.

activates the antero-superior fascicle area early (and consequently provides better activation for the papillary anterior muscle), and the lead placed classically in the apical area activates near the region of the postero-inferior fascicle. Due to the intrinsic delays of these two pacing points, we can obtain a simultaneous and more physiologic activation of the 2 papillary muscles with better performance of the mitral valve (Figure 6). Obviously, considering patients with severe dilated cardiomyopathy and advanced heart failure any reduction in the mitral regurgitation favors clinical improvement (Figure 8) (The randomized study of these cases with the Minnesota Living with Heart Failure Questionnaire has shown nearly a 50 % reduction in the symptoms). The follow-up in this group of patients will be very important because in patients paced for a long time, the reduction of the mitral regurgitation seems to be more important since heart failure has been clinically controlled (Figure 5).

Conclusion

In severe dilated cardiomyopathy with functional mitral regurgitation and wide QRS, endocardial right ventricular bifocal pacing significantly reduces functional mitral regurgitation, while conventional cardiac pacing promotes the mitral dysfunction. This effect for bifocal pacing seems to be due to a more physiologic activation of the papillary muscles and to a shortening

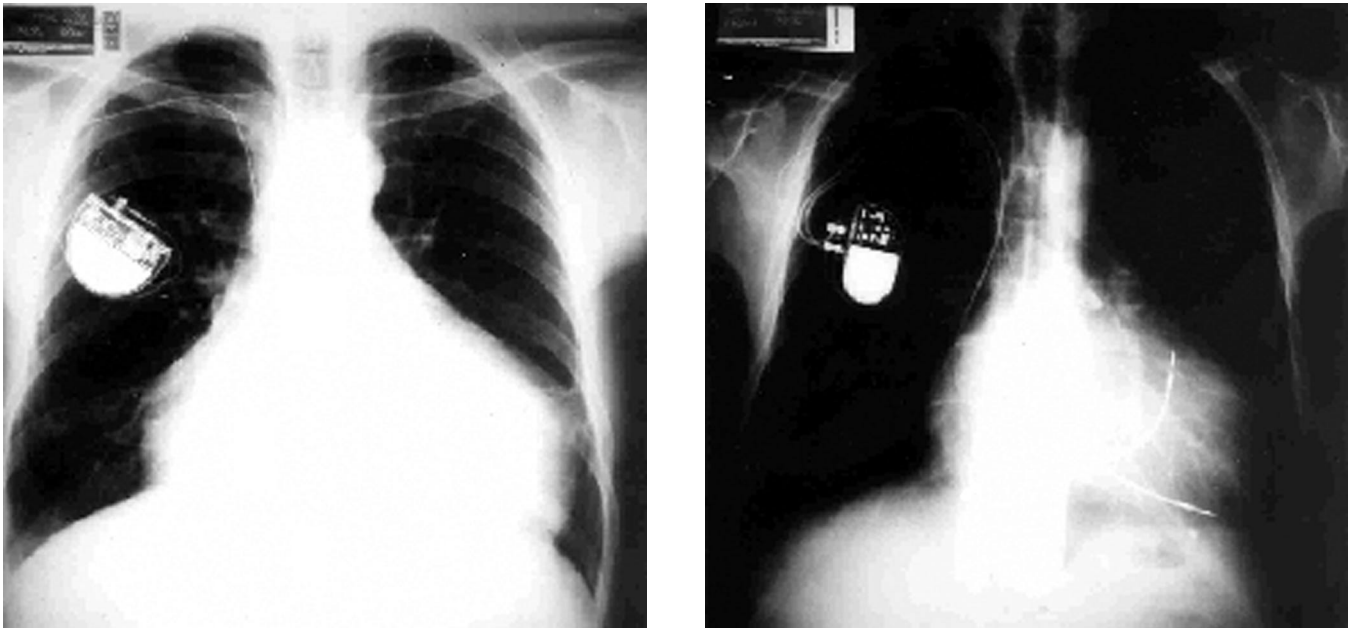


Figure 8. X-Ray comparison in Chagas' disease patient with long time conventional pacemaker (left). While electively replacing the old VVI pacemaker with a new one, we implanted one septal lead so that endocardial bifocal pacing was possible. After 9 days of right-ventricular bifocal pacing, there was significant reduction in cardiac size (right).

of the systole with reduction of the mitral regurgitation time. In addition, diastole is prolonged, with a significant improvement in diastolic function. These aspects and the easy implantation procedure are strong arguments for the clinical application of endocardial right bifocal pacing.

References

- [1] Xiao HB, Lee CH, Gibson DG. Effect of left bundle branch block on diastolic function in dilated cardiomyopathy. *Br Heart J.* 1991; 66(6): 443-7.
- [2] Hanna SR, Chung ES, Aurigemma GP, et al. Worsening of mitral regurgitation secondary to ventricular pacing. *J Heart Valve Dis.* 2000; 9(2): 273-5.
- [3] Cannan CR, Higano ST, Holmes DR Jr. Pacemaker induced mitral regurgitation: an alternative form of pacemaker syndrome. *Pacing Clin Electrophysiol.* 1997; 20(3,Pt.1): 735-8.
- [4] Auricchio A, Stellbrink C, Block M, et al. Effect of pacing chamber and atrioventricular delay on acute systolic function of paced patients with congestive heart failure. The Pacing Therapies for Congestive Heart Failure Study Group. The Guidant Congestive Heart Failure Research Group. *Circulation.* 1999; 99(23): 2993-3001.
- [5] Bakker PF, Meijburg H, Jonge N de, et al. Beneficial effects of biventricular pacing in congestive heart failure. *PACE.* 1994; 17: 820(abstract).
- [6] Cazeau S, Ritter P, Bakdach S, et al. Four chamber pacing in dilated cardiomyopathy. *PACE.* 1994; 17: 1974-9.
- [7] Gras D, Mabo P, Tang T, et al. Multisite pacing as a supplemental treatment of congestive heart failure: preliminary results of the Medtronic Inc. InSync Study. *PACE.* 1998; 21(11): 2249-55.
- [8] Pachon M. JC, Albornoz RN Pachon M. EI, et al. Right Ventricular Bifocal Stimulation in Dilated Cardiomyopathy with Heart Failure. Abstract - *Cardiostim 2000.*
- [9] Furman S, Robinson G. Stimulation of the ventricular endocardial surface in control of complete heart block. *Ann. Surg.* 1959; 150: 841.
- [10] Hayes DL. Evolving indications for permanent pacing. *Am J Cardiol.* 1999; 83(5B): 161D-165D.