

# Coronary Stenting in Cardiac Allograft Vasculopathy: The Impact of Silicon-Carbide Coating on Luminal Re-Obstruction

B. HEUBLEIN, R. KRECKSCH, K. PETHIG, A. HAVERICH

Hannover Medical School, Division of Thoracic and Cardiovascular Surgery, Hannover, Germany

C. VAN BIRGELIN

University of Essen, Department of Cardiology, Essen, Germany

## Summary

*An open, non-randomized, monocentric, observational angiographic study focusing on the assessment of the late outcome with respect to in-stent neointimal hyperplasia in 35 patients with discrete coronary lesions caused by transplant vasculopathy was done comparing uncoated (n = 40) and silicon carbide coated (n = 28) stents. It could be demonstrated by quantitative angiography that silicon carbide coated stents significantly reduced the neointimal formation at least over a 12-month time period after placement compared to uncoated stainless steel stents with identical lengths. The maximum of reintervention rate was reached after 18 months, obviously caused by the progression of the proliferative response at the stent margins and independently of stent surface coating.*

## Key Words

Stent coating, transplant vasculopathy, neointimal hyperplasia, restenosis

## Introduction

Cardiac allograft vasculopathy (CAV) remains one of the major obstacles to long-term survival after heart transplantation (HTx) [1]. CAV is characterized by diffuse intimal hyperplasia and discrete coronary lesions resulting from myointimal proliferation and vascular remodeling [2,3]. The long-term results of initially successful balloon angioplasty (PTCA) have been disappointing mainly due to a distinct recoil (early lumen loss) and/or restenosis (late lumen loss) [4-6]. Additional or primary stenting resulted in a significant improvement in luminal gain without increased periprocedural risk [7]. However, stents induce more neointimal formation than balloon angioplasty alone. Thus, restenosis remains highly problematic. This in-stent (re)stenosis may be caused by short-term responses to the stent implant involving a triggering of thrombosis and inflammation. The initial foreign-body reactions to the stent are certainly of importance for the late outcome. Improvements in hemocompatibility and

the reduction of cell adhesion and activation in the early phase after implantation indicate better results with respect to early and late complications after coronary stenting. Silicon carbide coating of metallic stents in vitro demonstrated significantly lower GpIIIa receptor-mediated platelet adhesion and CD11b receptor-mediated leukocyte adhesion [8]. Thus, we should expect better results with respect to hemocompatibility (stent thrombosis) and late lumen loss through the use of silicon carbide coated stents. HTx patients with CAV have a closed clinical and long-term angiographic follow-up. Adjuvant medical therapy is comparable over time. Based on promising results using stents in native coronary artery disease [9,10] and in CAV in general [7], we performed a comprehensive angiographic study focusing on the assessment of the eligible late angiographic outcome with respect to in-stent (re)stenosis and comparing both uncoated and silicon carbide coated stents.

<b>Patients</b>		n = 35
Stents		n = 68
Age of recipients (years)		45.5 ± 10.6
Time interval after transplantation (years)		6.10 ± 2.9
Male		n = 31
<b>Disease responsible for HTx</b>		
Dilatative cardiomyopathy		n = 20
Coronary heart disease		n = 11
Others		n = 4
Donor age		36.9 ± 10.2
<b>Stent locations (n)</b>		
Left anterior descending artery		30
Circumflex coronary artery		15
Right coronary artery		12
Diagonal branch		9
Intermediar		2
Implantation pressure (atm)		10.2 ± 2.2
Balloon size (mm)		3.2 ± 0.5

Table 1. Baseline characteristics of patient population, lesions and implantation data.

## Methods

### Patient Selection

35 patients (mean age 45.5 ± 10.6 years; 31 male) with 68 implanted coronary stents (28 silicon carbide coated, 40 uncoated stainless steel) were enrolled in this open, non-randomized, observational, monocentric study. The relevant patient- and lesion-related baseline characteristics are documented in Table 1. The following inclusion criteria provided an indication for catheter-based intervention with primary (without predilatation) or secondary (with predilatation) stent implantation:

- dominant lesion in the proximal or medial part of the vessel;
- minimal lumen diameter < 1.9 mm determined via intravascular ultrasound (IVUS) or < 50 % considering the IVUS-based reference vessel diameter after vasodilatation with 150 - 200 µg intracoronary nitroglycerine;
- reference vessel diameter > 2.5 mm (IVUS);
- length of stenosis < 14 mm;
- IVUS-based documentation of intimal flap;
- vessel-related myocardial area with normal or hypokinetic contractile function at rest. Bifurcation lesions were included; ostial lesions were excluded.

### Angioplasty - Stent - Procedure

After initial angiographic and IVUS assessment (motorized pullback, 30 MHz), standard stent implan-

tation was performed by monorail technique using pre-mounted or manually crimped stents with the balloon diameter adapted to the mean reference segment size (intended stent-vessel ratio 1:1; no oversizing). The stent-balloon system was dilated using balloon pressures between 8 and 12 atm (mean = 10.2 atm). In cases of only incomplete stent deployment (detected by angiography or IVUS), an additional dilatation with a 0.5 mm larger, high-pressure balloon was performed (n = 4; two in each group; 14 atm). Criteria for optimal stent-expansion were achieved when the in-stent diameter was angiographically (caliper method (Siemens highcore) or by IVUS (MLD) assessment) < 10 % of the proximal reference diameter. In two patients (one in both groups), a rotational or directional atherectomy was performed instead of stenting due to bifurcation lesion. The arterial sheaths were removed either one hour or immediately after the procedure. The arterial accesses were closed using an Angioseal device (Sherwood). Patients with an uncomplicated follow-up were discharged from the hospital the day after implantation.

### Stent Material/Design

Silicon carbide coated (n = 28) or uncoated stainless steel (n = 40) stents (identical lengths 14 mm) were implanted consecutively. As coated stents, we used semiconductor hybrid stents (first generation, Tensum, Biotronik). Different types of uncoated stents were used (Devon Medical, AVE, NIR, Cook-Roubin II, Sito), all of them consisting of 316L stainless steel. The expanded stent diameter ranged from 2.5 to 4.0 mm.

### Adjunctive Medical Treatment

Patients received only heparin during the procedure (loading dose 10,000 IU). No oral anticoagulants other than aspirin (300 mg p.d.) were administered over a period of one month. Immunosuppression was continued using a triple drug therapy with cyclosporine, azathioprine and steroids in all patients through the follow-up period. Patients received intracoronary isosorbide nitrate to achieve maximal dilatation (150 - 200 µg).

### Follow-Up/Endpoints

With respect to the late response after stenting, the relevant endpoint was the in-stent (re)stenosis/proliferation, defined angiographically. Six-month follow-up data were available from all of the eligible patients

who were stented with silicon carbide coated stents and 37 of the patients with uncoated stents (92.5 %). Quantitative coronary analysis (QCA) data were available from 19 coated (68 %) and 14 uncoated stents (35 %) at the 12-month interval, from 15 coated and 16 uncoated stents at the 18-month interval, and from 14 coated (50 %) and 4 uncoated stents at the 24-month interval. With respect to ethical considerations, a limited angiographic re-evaluation was conducted at long term follow-up. However, an absolutely complete clinical re-evaluation (no death, no myocardial infarction in the observed follow-up period) including ECG and echocardiography analysis was done in any case at any time-step. Coronary angiograms were recorded in multiple and standardized orthogonal projections in the Siemens High core system and stored on laser disc (Sony CRV, Laser Videodisc LVM-3AAO).

Angles and rotations of projections were documented and readjusted for the recordings of control angiograms immediately after stenting and with respect to the follow-up time intervals. The laser discs were sent to the laboratory at the University of Essen for quantitative assessment (QCA). After re-digitalization, the quantitative evaluation will be performed by the Cardiovascular Measurement System (CMS) using a standard protocol and the guiding catheter for calibration by an independent, experienced cardiologist [11].

As reference diameters of the stented segment, 2 mm from each of the proximal and the distal margins of the stent were defined. The minimal lumen diameter (mm) and the cross-sectional area (mm<sup>2</sup>) are calculated from the different regions proximal to, within, and distal to the stent. Clinically relevant in-stent (re)stenosis was defined as a 50 % diameter stenosis within or immediately (+/-) adjacent to the stent.

#### Statistical Analysis

All data are presented as a mean/standard deviation unless stated otherwise. The principal analysis consisted of a signal comparison between the studied groups with respect to the defined endpoint. Student's t-test for independent probes (SPSS statistical package) was used to compare differences between groups. The Kolmogorov-Smirnow test was used to examine the normal distribution. Event-free frequencies after stent placements, defined by the rate of re-intervention at the same stent, were determined by Kaplan-Meier technique. P-values < 0.05 were considered to be significant.

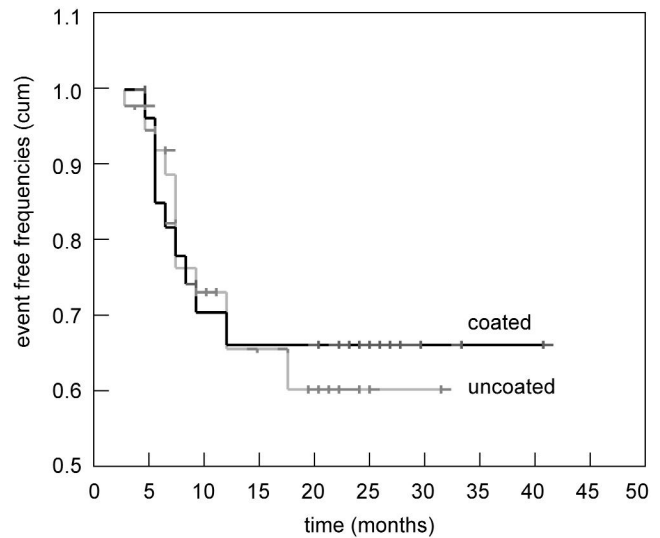


Figure 1. Rate of re-intervention during follow-up after coronary implantation of a-SiC:H-coated and uncoated stents.

## Results

### Clinically Relevant In-Stent (Re)Stenosis/Event-Free Frequencies

The maximum rate of stent re-intervention for both groups was reached at 18 months after stent placement (Figure 1). In general, 9 events (out of 28 implanted stents) in the coated group and 12 events (out of 40 implanted stents) in the uncoated group were recorded at the 24-month follow-up. The obviously stable difference between these event-rates later than 18 months after stent placement was not significant (log rank).

### Minimal Lumen Diameter

With respect to the coated stent group, the minimal lumen diameter (MLD) decreased significantly from 2.63 mm to 2.27 mm after 6 months. At the follow-up time, the MLD increased again to 2.44 mm after 24 months (Figure 2). The mean maximal difference between early and late lumen gain was 0.36 mm. In the uncoated stent group, the MLD decreased significantly from 2.35 mm to 1.79 mm after 6 months (Figure 2) and reached the minimum at 12 months with 1.69 mm, increasing slightly and insignificantly to 2.05 mm at 24 months after stent placement. The mean maximal difference between early and late lumen gain was 0.66 mm, a significant difference in comparison to the coated group at 6 and 12 months. As expected, the

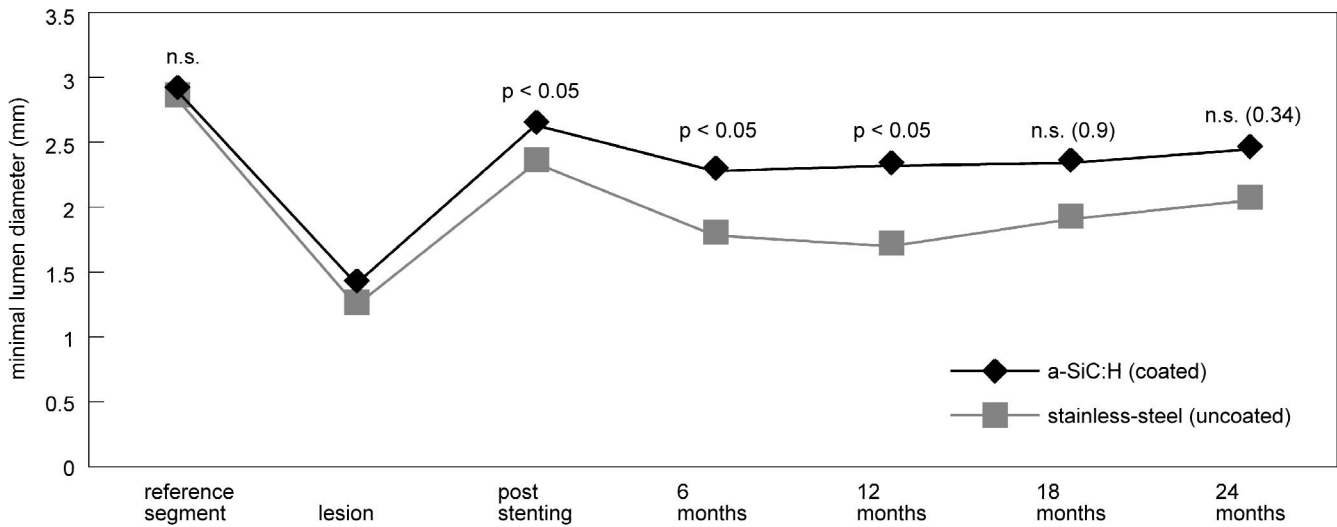


Figure 2. Minimal lumen diameter (quantitative coronary angiography) at different time before and after stent placement using a-SiC:H-coated and uncoated (stainless-steel) stents.

cross-sectional areas demonstrated the same development (Figure 3). At the 12-month follow-up, the maximum drop was only 0.94 mm<sup>2</sup> in the group with coated stents, whereas the analogue assessment in the group with uncoated stents revealed a maximum decay of 1.87 mm<sup>2</sup>.

*Proximal and Distal Stent Margins*

Twelve months after stent placement, the maximum decrease in the proximal MLD was from 2.63 mm to

2.36 mm in the coated group and from 2.35 mm to 1.98 mm in the uncoated group. With respect to the distal segments, the differences were not significant between the two groups as shown in Table 2.

**Discussion**

In this follow-up study of a clearly defined patient population with transplant vasculopathy, we demonstrated that a silicon carbide coated stent surface

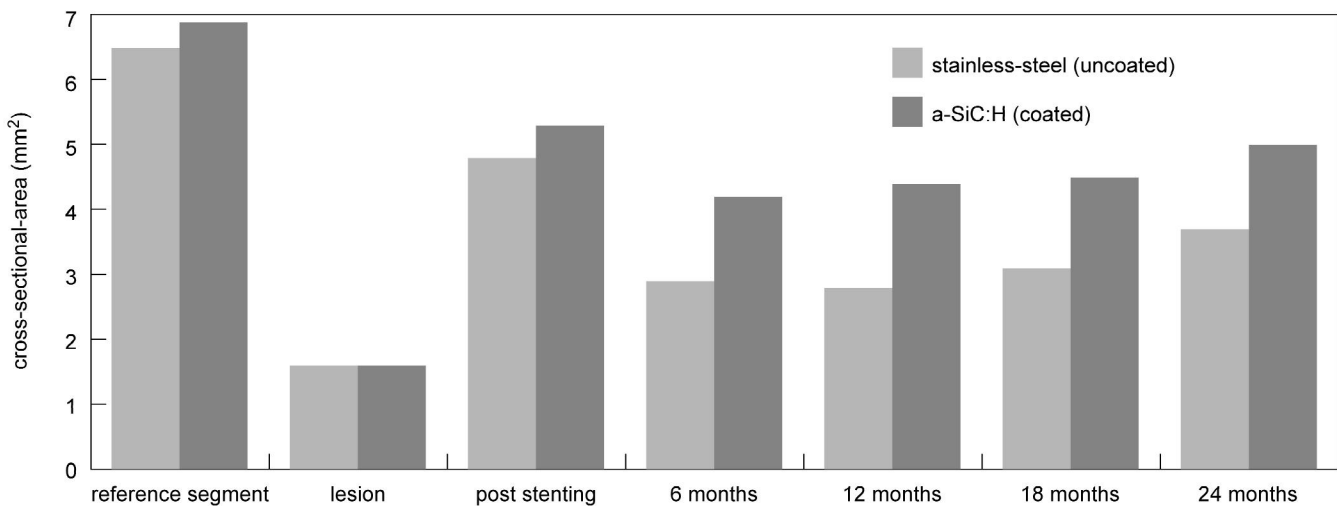


Figure 3. Cross-sectional areas [mm<sup>2</sup>] (QCA) at different times before and after stent placement using a-SiC:H-coated and (stainless-steel) uncoated stents.

(Tensum, Biotronik) significantly reduced neointimal formation at least over an 18-month period after placement compared to uncoated stainless steel stents. Previous data from animal and human studies presented strong evidence that post-injury neointimal hyperplasia, and therefore the development of restenosis, are linked to platelet adhesion, activation, aggregation, and thrombus formation [12,16,17]. In addition, recent published data revealed a role of mural thrombus organization for in-stent (re)stenosis [18].

However, some conflicting clinical data on the long-term benefit of GpIIb/IIIa inhibitors exist, and support the hypothesis that early thrombus deposition and the consecutive release of growth factors like platelet-derived mediators are not solely responsible for the development of exaggerated, neointimal proliferation [19]. Besides stent thrombosis and permanent mechanical stress, leukocyte adhesion and activation — and, consecutively, local inflammation — might be important for late neointimal formation [8,12,20]. Using well-known electrochemical interactions in fibrin monomer formation at the alloplastic surfaces [14], the coating of a metallic surface with a thin semiconductor layer assures improved hemo- and biocompatibility of the device [15]. A positive influence both in the local thrombogenicity and inflammation at the stent surface with regard to in-stent (re)stenosis might be expected. The *in vitro* assessment of the silicon carbide coating demonstrated the expected inhibition of fibrin polymerization and, in addition, revealed significantly lower GpIIIa receptor-mediated platelet adhesion in comparison to an uncoated stainless steel surface [8]. Clinical data in a patient population with high risk for acute or subacute coronary stent thrombosis confirm this observation [9,10,21]. A comparative analysis of silicon carbide coated Biotronik stents with stainless steel Palmaz-Schatz stents demonstrated that the amount of CD11b receptor antigen-binding representing leukocyte adherence was significantly lower on the coated surface [22]. This combination of local thrombus inhibition and the lowering of local inflammatory responses should have clinical relevance for a potential reduction of late local response after stent placement. Considering that no significant differences were observed between the corresponding groups with respect to the pre-placement implantation parameters, a significant diminishing of the neointimal formation using silicon carbide coated stents could be demonstrated at least 6 and 12 months after implantation

Significance	Coated			Uncoated		
	n	m	SD	n	m	SD
<b>Proximal</b>						
immediately after ( $p < 0.05$ )	28	2.63	0.45	40	2.35	0.45
6 months fu (n.s.)	26	2.51	0.82	35	2.25	0.66
12 months (n.s.)	17	2.36	1.03	14	1.98	0.73
18 months ( $p < 0.05$ )	10	2.39	0.74	15	2.00	0.59
<b>Distal</b>						
immediately after ( $p < 0.05$ )	28	2.63	0.45	40	2.35	0.45
6 months fu (n.s.)	28	2.21	0.65	37	1.93	0.65
12 months (n.s.)	18	2.10	0.75	13	1.62	0.72
18 months (n.s.)	14	2.28	0.58	16	1.88	0.57

Table 2. Minimal lumen diameter (QCA) [mm] at the proximal and distal stent margins with regard to different times before and after stent-placement using a-SiC:H-coated and uncoated stainless-steel stents.

(Figure 2). The corresponding proliferative response at the proximal margins (Table 2) is only significantly different after 18 months. This regional-type and the time interval suggest an induction of neointimal formation over this time by the permanent rigidity and distensibility of the stents in both groups independent of the surface characteristics. Clinically relevant is the development of re-stenosis leading to re-intervention or complication (event free frequencies).

In both groups, the maximum rate of stent re-intervention was reached at 18 months (Figure 1). However, in this observed target lesion revascularization, the re-interventions caused by significant (> 50 %) re-obstructions of the stent margins (proximal and distal) are included. With respect to a 6-month interval and confined to the real in-stent (re)stenosis, the restenosis rates were 12 % (coated) and 15 % (uncoated) without a further increase in the 12-month interval. Thus, we suggest that the progression in the proximal stent margins is responsible for the increasing rate of stent re-intervention and not the in-stent (re)stenosis itself. The adverse neointimal proliferative process is related to the permanent mechanical stress by the permanent foreign body and is obviously not changeable by the surface characteristics.

### Limitations

- This was a single-center observational study on a small patient population.
- The post-placement early luminal gain was different for each group.

- Because of ethical concerns, the QCA follow-up is incomplete. This might have influenced the comparative analysis of QCAs, but not the event frequency follow-up. In any case, a closed clinical follow-up integrating objective evidence of myocardial ischemia using usual diagnostic procedures was conducted throughout the reported follow-up period.
- Different types of stents (design) were used for comparative analysis. This limits the statistical validity of the comparison, as some stent types may be superior to others. The eligible number of stents is too small to analyze the potential influence of stent design on the given results.

### Conclusions

The clinically relevant restenosis rate after stenting in cases of transplant vasculopathy is favorably low independent of the stent surface characteristics. A standard 6-month follow-up is not enough to exclude relevant obstructions. The maximum re-intervention rate is expected after 18 months, obviously caused by the progression of the proliferative response at the proximal stent margins. Compared to uncoated stainless steel surfaces, silicon carbide coating significantly diminished the in-stent proliferative response at least 12 months after coronary stent placement.

### References

- [1] Hosenpud JD, Novick RJ, Bennett LE, et al. The registry of the International Society for Heart and Lung Transplantation: Thirteenth Official Report. *J Heart Lung Transplant*. 1996; 15: 655-674.
- [2] Pethig K, Heublein B, Wahlers T. Impact of plaque burden on compensatory enlargement of coronary arteries in cardiac allograft vasculopathy. *Am J Cardiol*. 1997; 79: 89-92.
- [3] Pethig K, Heublein B, Wahlers T, et al. Mechanism of luminal narrowing in cardiac allograft vasculopathy: Inadequate vascular remodeling rather than intimal hyperplasia is the major predictor of coronary artery stenosis. *Am Heart J*. 1998; 135: 628-633.
- [4] Christensen BV, Meyer SM, Iacarella CL et al. Coronary angioplasty in heart transplant recipients: a quantitative angiographic long-term follow-up study. *J Heart Lung Transplant*. 1994; 13: 212-220.
- [5] Halle AA, Disciascio G, Massin EK, et al. Coronary angioplasty, atherectomy and bypass surgery in cardiac transplant recipients. *J Am Coll Cardiol*. 1995; 26: 120-128.
- [6] Swan JW, Norell M, Yacoub M, et al. Coronary angioplasty in cardiac transplant recipients. *Eur Heart J*. 1993; 14: 65-70.
- [7] Heublein B, Pethig K, Maaß C, et al. Coronary artery stenting in cardiac allograft vascular disease. *Am Heart J*. 1997; 134: 930-938.
- [8] Monnick SHJ, Boven AJ van, Peels HJ, et al. Silicon - carbide coated coronary stents have low platelet and leukocyte adhesion during platelet activation. *J Investig Med*. 1999; 47: 304-310.
- [9] Heublein B, Özbek C, Pethig K. Silicon carbide coated stents: Clinical experience in coronary lesions with increased thrombotic risk. *J Endovasc Surg*. 1998; 5: 32-36.
- [10] Heublein B, Pethig K, Elsayed AM. Silicon-carbide coating - a semiconducting hybrid design of coronary stents. A feasibility study. *J Invas Cardiol*. 1998; 10: 255-262.
- [11] Reiber JHC, Serruys PW, Kooijman CJ, et al. Assessment of short-, medium- and long-term variations in arterial dimensions from computer-assisted quantitation of coronary cineangiograms. *Circulation*. 1985; 71: 280-288.
- [12] LeBreton H, Plow E, Topol EJ. Role of platelets in restenosis after percutaneous coronary revascularization. *JACC*. 1996; 94: 1247-1254.
- [13] Serruys PW, Emanuelsson HU, Giessen W van der, et al. Heparin-coated Palmaz-Schatz stents in human coronary arteries - early outcome of the Benestent - II pilot study. *Circulation*. 1996; 93: 412-422.
- [14] Baurtschmidt P, Schaldach M. The electrochemical aspects of the thrombogenicity of a material. *J Bioeng*. 1977; 261-278.
- [15] Amon M. Die Entwicklung röntgendichter Koronarstents mit einer blutverträglichen Beschichtung aus amorphem Siliziumkarbid für die interventionelle Kardiologie. Schiele & Schön, Berlin, 1997.
- [16] Unterberg C, Sandrock D, Nebendahl K, et al. Reduced acute thrombus formation results in decreased neointimal proliferation after coronary angioplasty. *J Am Coll Cardiol*. 1995; 26: 1747-1754.
- [17] Sirois MG, Simons M, Kuter DJ, et al. Rat arterial wall retains myointimal hyperplastic potential long after arterial injury. *Circulation*. 1997; 96: 1291-1298.
- [18] Komatsu R, Ueda M, Naruko T, et al. Neointimal tissue response at sites of coronary stenting in humans. *Circulation*. 1998; 98: 224-233.
- [19] Kereiakes DJ, Lincoff AM, Miller DP, et al. EPILOG Trial Investigators. Abciximab therapy and unplanned coronary stent deployment: favorable effects on stent use, clinical outcomes, and bleeding complications. *Circulation*. 1998; 97: 857-864.
- [20] Inoue T, Sakai Y, Hoshi K, et al. Lower expression of neutrophil adhesion molecule indicates less vessel wall injury and might explain lower restenosis rate after cutting balloon angioplasty. *Circulation*. 1998; 97: 2511-2518.
- [21] Scheller B, Hennen B, Severin-Kneib S, et al. Follow-up of the PSAAMI study population (primary stenting vs. Angioplasty in acute myocardial infarction). *J Am Coll Cardiol*. 1999; 33(suppl. A): 29A.
- [22] Monnick, SHJ, Tigchelaar I, Boven AJ van, et al. Biocompatibility of the amorphous silicon carbide coated Biotronik stent. *Circulation*. 1998; 98(suppl.): 1016.