

The Ventricular Myocardium Repolarization Process and its Peculiarities in Wolff-Parkinson-White Syndrome

I.P. POLYAKOVA, A.SH. REVISHVILI, L.A. BOCKERIA

Bakoulev Research Centre for Cardiovascular Surgery of Russian Academy of Medical Sciences, Moscow, Russia

Summary

Radiofrequency ablation (RFA) of accessory atrioventricular pathways (AAVP) seems to be the most preferable therapeutic method in the treatment of Wolff-Parkinson-White syndrome (WPW). Correct identification of post-ablation ECG changes is possible only if depolarization and repolarization process features are established in instances of WPW syndrome. The goal of our investigation was to clear up peculiarities of the ventricular repolarization process in cases of WPW syndrome and whether repolarization disturbances are sustained after the myocardium excitation pattern changes. We analyzed the surface ECG mapping (SM) data of 112 patients with persistent and intermittent forms of WPW and different AAVP localization prior to and after the RFA of AAVP, as well as patients undergoing RFA due to other forms of supraventricular arrhythmia. It has been shown that in persistent WPW syndrome, an anomaly of ventricle repolarization exists. Its degree depends on AAVP localization, and on the degree of pre-excitation for parietal AAVP. In paraseptal, anterior, and posterior AAVPs, the ventricular repolarization process direction is opposite to the depolarization process direction; different values of appropriate electric axes serve as an additional diagnostic feature to localize anomalous conduction paths and to discriminate paraseptal and parietal AAVP. Post-ablation repolarization anomalies are more evident in patients with persistent pre-excitation syndrome and are related mainly to the anomalous depolarization process. Localization of maximal and minimal STT integral over the surface ECG immediately after the RFA procedure coincides with the localization of, appropriately, maximal and minimal values of the delta wave prior to the RFA procedure in patients with any AAV, (except right).

Key Words

Wolff-Parkinson-White syndrome, ventricular myocardium repolarization, surface ECG mapping, radiofrequency ablation

Introduction

Although the preexcitation syndromes, especially Wolff-Parkinson-White (WPW), are considered to be a well-known electrophysiological phenomenon [1,2] only a few authors mention that WPW syndrome is associated with repolarization abnormalities [3,4]. Previously, the ventricular myocardium repolarization process and its features in WPW patients attracted less attention than depolarization abnormalities caused by accessory atrioventricular pathways (AAVP).

Currently, "closed" methods, i.e. catheter treatment methods, are preferable among nonmedication WPW

treatment methods. As reported elsewhere [5], the optimized balance between patient safety and procedure efficiency could be achieved. Myocardium application is well localized and the risk of myocardial damage is small due to small application power. Nevertheless, we have paid attention to electrocardiographic features of myocardium repolarization abnormalities in WPW patients after radiofrequency ablation (RFA) procedures. Several publications [4,6-9] point to the fact that these features appearing after catheter ablation are temporary, disappear in 6 weeks and are not related to

myocardial damage. The authors relate them to the "cardiac memory" phenomenon introduced by Rosenbaum [10], assuming the cardiac muscle memorizing of repolarization abnormalities for some period of time (up to several weeks)

However, only a few works mention (along with postablation myocardium changes) the relationship of WPW syndrome with repolarization abnormalities. Correct identification of postablation myocardium repolarization changes is possible only if process peculiarities caused by the WPW syndrome are known.

We have extensively studied ECG investigations or surface ECG mapping (SM) data in patients with persistent and intermittent WPW syndrome prior and after RFA, as well as in patients with other forms of supraventricular arrhythmia subjected to the RFA procedure. The task was to reveal ventricular myocardium repolarization peculiarities in persistent WPW syndrome and to clear up whether repolarization disturbances are maintained during myocardium excitation pattern changes.

Materials and Methods

We analyzed the SM data of 112 persistent WPW patients (pts) (63 male and 49 female, mean age 29.5 ± 13.7 years) without associated cardiac pathology and with different AAVP localization confirmed by inva-

sive electrophysiological investigation (EPI). Left localized AAVPs were in 46 pts, septal and posterior paraseptal in 30 pts, right in 22 pts, anterior septal and anterior paraseptal in 14 pts.

Intermittent WPW syndrome was registered by SM in 10 pts (8 male and 2 female, mean age 24.4 ± 14.0 years). Left localized AAVP was in 3 pts, septal and posterior paraseptal in 3 pts, right in 2 pts, anterior septal in 2 pts.

The SM was also performed in 39 pts after successful RFA of persistent AAVP. Left AAVP localization was in 15 pts, septal and posterior paraseptal in 7 pts, right in 11 pts, anterior septal and anterior paraseptal in 6 pts. Intermittent WPW was in 3 pts (anterior septal AAVP localization in one pt, right anterior AAVP localization in one pt, left posterior AAVP localization in one pt).

SM data prior to and after the RFA procedure have also been studied in patients with other forms of supraventricular arrhythmias. Among them were 5 pts with hidden forms of WPW syndrome and different AAV localization and 5 pts with AV-node tachycardia (mean age 24.9 ± 13.4 years).

The investigation was performed prior to the RFA procedure, during the first 2 days after the RFA procedure (the mean time after procedure was 31.3 ± 8.2 hours) and in long-term follow-up (3-6 months).

The control group was comprised of 20 healthy subjects (mean age 21.8 ± 4.6 years).

| AAVP localization | Angle [EOS_{QRS} - EOS_{ST-T}] fr (normal 23.5 ± 11°) | Interposition of QRS and ST-T vectors (ST-T follows QRS in normal) |
|---|---|---|
| left | from +30.0 ± 94.6° for anterior lateral to -13.6 ± 75.7° for posterior | |
| posterior septal and posterior paraseptal | -144.9 ± 30.4° +121.0 ± 31.5° = EOS _{QRS} - EOS _T -24.2 ± 15.0° | ST-T opposite to QRS |
| right | from -126.5 ± 50.3° for posterior lateral to +120.6 ± 78.9° for anterior lateral | |
| anterior septal and anterior paraseptal | +172.2 ± 27.6° +122.0 ± 25.9° = EOS _{QRS} - EOS _T -47.7 ± 11.0° | ST-T opposite to QRS |

Table 1. Peculiarities of QRS and ST-T vectors interposition along frontal plane in different AAVP localizations.

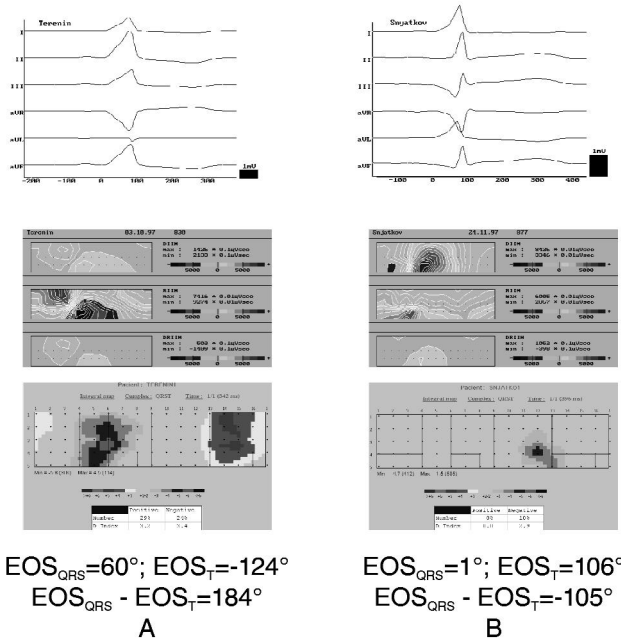


Figure 1. Ventricular myocardium repolarization analysis in patients with persistent WPW syndrome. Standard ECG leads, isointegral QRS, ST-T and QRST maps and differential QRST maps. Angles below are $EOS_{QRS} - EOS_{ST-T}$. Each map is presented on the thoracic surface scan which is cut along the right posterior-axillary line. A) anterior paraseptal AAVP localization; B) posterior paraseptal AAVP localization.

Surface mapping

During the SM procedure, signals were recorded in 12 standard Frank orthogonal ECG leads and 80 chest unipolar leads ("Cardiag 128.1" specialized system) registered simultaneously. The electrodes were located in regular netting across the 1st to 6th ribs on the thoracic surface. SM data were presented as simultaneous isopotential map sequences of the whole cardiac cycle, as a T-wave amplitude distribution map, and as isointegral QRS, ST-T and QRST interval maps. Also differential maps were plotted, in which the so-called "departure index" (DI) or normal difference of patient-integrated characteristics and of corresponding mean "normal" characteristics were calculated. The absolute value deviations exceeding 2 ($|DI| > 2$) were significant. The repolarization process was evaluated by T-wave amplitude, by the area under the ST-T curve in different leads, and by localization of appropriate extremities. With differential maps on QRS, ST-T, and QRST intervals, the minimum negative - DI and max-

imum positive +DI deviations (from normal) of the surface manifestations of the de- and repolarization processes could be evaluated. Also their localization (of deviations) on the thoracic surface and mean volume (-DI) in % or (+DI) in % (in surface percentage on the thoracic surface) might be evaluated. The ventricular myocardium repolarization direction was evaluated from QRS and ST-T electrical vectors differences in the frontal and horizontal planes

Radiofrequency ablation

During invasive EPI, the EPI parameters, diagnosis, and utmost early excitation point were defined. An ablation catheter-electrode was introduced under X-ray control for RF power application. The application power was set at gradual increments ranging from 5 to 50 W, the duration was up to 1-1.5 min, the temperature was controlled to be in the range of 50-60 °C, and the number of applications was 1 to 25.

In 13 pts (persistent WPW syndrome and different AAVP localization in 7 pts; other supraventricular tachyarrhythmia forms in 6 pts) the control enzyme activity measurements in blood plasma were performed: using general KFK and MB isoenzyme exactly prior to RFA, and were also measured within 24 hours after the RFA procedure in 4 hour intervals.

Statistical analysis

Data bases using Excel tables have been created to process the SM data of patients and healthy subjects. Sampling characteristics are presented as $M \pm SD$, with M-mean values, and SD-standard deviation. Statistical data processing was performed using Statistika program software for Windows 95.

Results

Control group

T wave amplitude distribution maps, QRS, ST-T and QRST interval isointegral maps were uniform in the control group. They were dipolar, with maximum in the precordial area and with minimum on the right shoulder, in the case of T-wave map and ST-T and QRST isointegral maps. The minimum was observed in the upper middle part of the thoracic front wall for QRS isointegral map (Figure 1). QRS and ST-T electrical vector difference was $+23.5 \pm 10.9^\circ$ (from 3 to 44°) in the frontal plane, and $-47.4 \pm 27.7^\circ$ (from -4 to -85°) - in the horizontal plane.

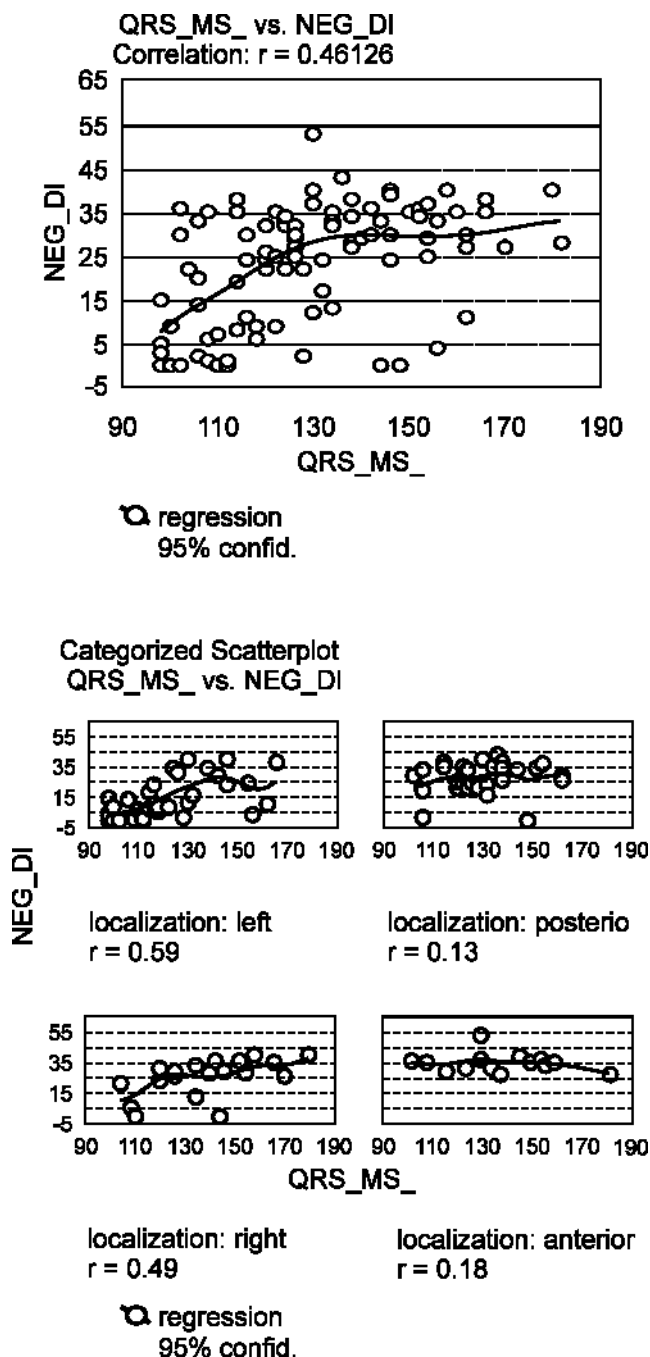


Figure 2. Negative DI values vs. *QRS_MS* dependence derived from differential isointegral maps. Upper panel - general characteristic; lower panel - divided into groups according to the AAVP localization.

Manifesting WPW syndrome

In all AAVP localizations the extreme shift (mostly negative) in T-wave amplitude distribution was

observed, reflected also in the extreme shift on the ST-T isointegral map (Figure 1).

The values of different angles between QRS and ST-T electrical vectors in the frontal plane at different AAVP localization are demonstrated in Table 1. These data proved that at ventricular myocardium preexcitation, the repolarization direction can be opposite to the depolarization direction or can significantly deviate from it depending on the AAVP localization, in contrast to the normal process (where both vectors deviate only slightly). Asynchronous excitation of ventricular myocardium paraseptal areas abruptly changes the sum repolarization process, and the repolarization direction becomes opposite to the depolarization direction.

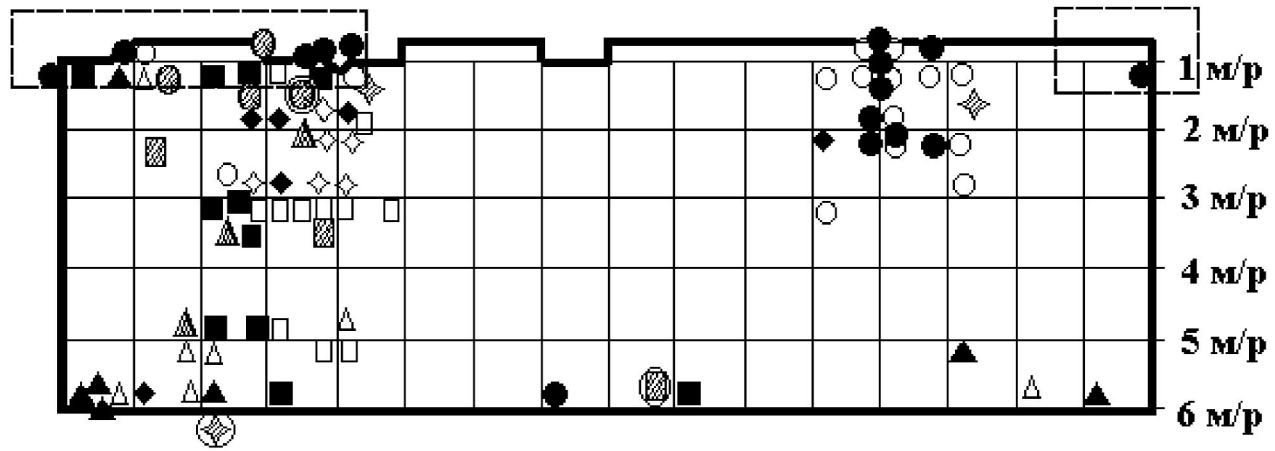
Different isointegral maps and DI negative values in patients with persistent WPW and different AAVP localizations were studied to evaluate a possible relationship between surface abnormalities in ventricular myocardium repolarization and pre-excitation degree, which is expressed indirectly in QRS complex duration. The results are shown in Figure 2. The increase of repolarization deviation from normal with pre-excitation increasing (Figure 2 above, $r = 0.46$) is most significant in the cumulative analysis of cases of early ventricular myocardium preexcitation.

Figure 2 shows the data divided into 2 groups according to AAVP localization. In parietal left and right AAVP the dependence becomes more evident ($r = 0.59$ and $r = 0.49$, respectively). However, the front and back paraseptal AAVP DI_{ST-T} dependence on QRS duration is less definite. In front paraseptal AAVP with QRS increasing, the DI_{ST-T} decreasing can be observed ($r = 0.13$ and $r = -0.18$, respectively).

While QRS duration values at different AAVP localization did not differ significantly, repolarization deviation was maximal in paraseptal AAVP and minimal in left ones, $35 \pm 6.2\%$ and $14.24 \pm 13.1\%$ ($p < 0.025$), respectively.

Intermittent WPW syndrome

In all pre-excitation cases, all surface distribution characteristics and QRS and ST-T angle differences in the frontal plane correspond to those AAVP localization. For example, on the QRS isointegral maps the minimum was located on that thoracic surface part where negative delta waves are registered; the QRS and ST-T angle difference in the frontal surface was $+202^\circ$ and $+187^\circ$ in anterior septal AAVP localization, being $-148 \pm 5^\circ$ in posterior paraseptal.



| AAVP localization | -QRS _{min} before RFA | -T _{min} after RFA of AAVP | -T _{min} by intermittent AAVP without pre-excitat. | -T _{min} after RFA of intermittent AAVP |
|------------------------------|--------------------------------|-------------------------------------|---|--|
| anterior and anterior septal | ☆ | ◆ | ☆ | ☆ |
| right | □ | ■ | □ | □ |
| posterior paraseptal | △ | ▲ | △ | △ |
| left | ○ | ● | ○ | ○ |

Figure 3. Localization (intercostal space number) of surface features of ventricular myocardium repolarization abnormalities in persistent and intermittent WPW syndrome without pre-excitation prior to and after RFA of AAVP of different localization.

However, the differences from mean normal in surface distributions were also observed without pre-excitation. That could be noticed in the disposition of QRS and ST-T vectors on differential maps as well. In 9 out of 10 cases, the QRS vector direction, which characterizes the direction of the integral depolarization process, was within normal limits. In 9 out of 10 cases the abnormal QRS and ST-T vector disposition was determined by direction of the anomalous repolarization process. However, differential QRS and QRST-T isointegral maps have revealed deviations of total de- and repolarization processes from normal.

Figure 3 depicts the thoracic surface for patients with intermittent WPW syndrome and different AAVP. Also shown are QRS_{min} localization at ventricular myocardium pre-excitation, i.e. leads with minimal

negative delta wave; and T_{min} localization in the absence of pre-excitation, i.e. leads with minimal negative T wave amplitude. In the absence of pre-excitation, the negative T wave is localized in the "normal" area only in left AAVP, while registered beyond this area at other AAVP localization. Only in 1 out of 3 pts with posterior paraseptal AAVP localization, the negative T-wave without pre-excitation was registered within the area where the negative delta wave was registered at ventricular myocardium pre-excitation.

Surface mapping after RFA procedure

Tables 2 & 3 summarize peculiar features of ventricular depolarization and repolarization processes prior to and after the RFA of persistent WPW syndrome and other supraventricular arrhythmia forms.

| AAVP localization | Prior to RFA | | After RFA | | (pr. RFA) vs (after RFA) |
|---|------------------------------------|------------------------|--------------------------------------|------------------------|--------------------------|
| | %(-DI) _{QRS} | -DI _{QRS min} | %(-DI) _{QRS} | -DI _{QRS min} | |
| left (n=15) | 31.13 ± 10.9 | -8.85 ± 3.5 | 10.33 ± 14.1 (less than 2% in 8 pts) | -2.89 ± 1.3 | p < 0,0001 |
| posterior septal and posterior paraseptal (n = 7) | 37.14 ± 10.0 | -9.5 ± 2.8 | 11.28 ± 12.4 (less than 2% in 3 pts) | -3.06 ± 1.3 | p < 0.001 |
| right (n = 11) | 39.33 ± 9.7 | -9.3 ± 3.5 | 2.75 ± 5.8 (less than 2% in 6 pts) | -2.06 ± 0.8 | p < 0.001 |
| anterior septal and anterior paraseptal (n = 6) | 46.33 ± 6.5 | -14.33 ± 3.9 | 9.6 ± 17.1 (less than 2% in 3 pts) | -2.6 ± 1.0 | p < 0.0015 |
| hidden WPW syndr. and nodal tachycardia (n = 10) | 2.87 ± 4.1 (less than 2% in 6 pts) | -2.24 ± 0.5 | 3.85 ± 4.2 (less than 2% in 4 pts) | -2.4 ± 0.7 | p = NS |

Table 2. Ventricular myocardium depolarization features in persistent WPW and other SV arrhythmia patients prior to and after RFA (differential isointegral QRS map parameters).

Immediately following the RFA of persistent AAVP, the changes in QRS waveform corresponding to ventricular depolarization pattern changes are observed in ordinary 12 lead ECGs. QRS vector direction without pre-excitation gets into normal values. The thoracic part with vivid deviations of QRS complex configuration from normal is definitely reduced on the differential maps (Table 2). In one patient with anterior septal AAVP, all surface distributions showed pre-excitation features, because RFA of an abnormal path modified its electrophysiologic characteristics but did not divert it.

The signs of repolarization process disturbances are noticed simultaneously with these changes. According to the 12-lead ECG, they are the following: the T lowering or even its inversion in V1-V2 leads, or T inversion in I, III, F leads, or T increasing in precordial V2-V6 leads. T wave amplitude significantly increases in V1-V3 or V4 leads, fewer changes are observed in V5 and V6.

Figure 3 shows that after RFA, the negative T wave was localized in the same area where the negative delta wave was localized prior to RFA [or QRSm_{in}, in 8 left

AAVP pts (53.3%), in 6 posterior paraseptal AAVP pts (54.5%), in 6 right AAVP pts (54.5%) and in 4 anterior paraseptal AAVP pts (80% of successfully eliminated AAVPs)].

No correlation was revealed between the deviations on the post-ablation differential QRS map and the negative T wave localization. Thus, in patients with "normal" QRS mapping, the negative T wave was localized in the "normal" area as well as in the area of the negative delta wave prior to ablation.

The following was observed in 3 RFA cases of intermittent WPW syndrome: in right and left AAVP localization patients, the T_{min} after RFA and without pre-excitation coincided, although it was not the area of the negative delta wave registration (Figure 3). In patients with the anterior septal AAVP localization, the T_{min} after RFA and without pre-excitation did not coincide with each other, nor with the delta wave localization on the ECG prior to RFA.

Quantitative analysis of the deviation in the repolarization process from the mean "normal" process according to differential ST-T and QRST maps reveals the deviation depending on different AAVP localizations (Table 3).

| AAVP localization | Prior to RFA | | After RFA | | (pr. RFA) vs (after RfA) |
|---|--------------------------------------|------------------------|-------------------------------------|------------------------|-----------------------------|
| | %(-DI) _{QRS} | -DI _{QRS min} | %(-DI) _{QRS} | -DI _{QRS min} | |
| left (n = 15) | 10.4 ± 9.4 (less than 2% in 3 pts) | -4.04 ± 1.7 | 12.1 ± 10.8 (less than 2% in 3 pts) | -4.0 ± 1.35 | P = NS |
| posterior septal and posterior paraseptal (n = 7) | 7.71 ± 10.1 | -5.08 ± 1.5 | 17.57 ± 13 (less than 2% in 2 pts) | -4.01 ± 0.8 | P = NS |
| right (n = 11) | 18.89 ± 11.8 (less than 2% in 2 pts) | -4.58 ± 1.6 | 7.25 ± 5.8 (less than 2% in 3 pts) | -3.05 ± 0.9 | p < 0.033 |
| anterior septal and anterior paraseptal (n = 6) | 17.6 ± 9.3 (less than 2% in 1 pt) | -5.08 ± 2.3 | 8.2 ± 6.4 (less than 2% in 1 pt) | -3.34 ± 1.3 | P = NS |
| hidden WPW syndr. and nodal tachycardia (n = 10) | 2.12 ± 2.9 (less than 2% in 8 pts) | -2.28 ± 0.6 | 4.85 ± 5.0 (less than 2% in 5 pts) | -2.81 ± 0.7 | P = NS |

Table 3. Ventricular myocardium repolarization features in persistent WPW and other SV arrhythmia patients prior and after RFA (differential isointegrated QRST map parameters).

The analyzed results of the possible influence of pre-excitation rate on post ablation repolarization disturbances are depicted in Figure 4. They reveal a relatively weak correlation of these effects in left, $r = 0.14$ and posterior septal AAVP, $r = -0.23$, and a little stronger correlation in anterior septal AAVP, $r = 0.35$. In case of right AAVP, the pre-excitation rate depends on post ablation repolarization disturbances in the same way as in repolarization disturbances prior to ablation, $r = 0.48$ ($r = 0.49$, Figure 2).

Minimal-negative ($-DI_{QRSTmin}$) values in left AAVP are localized mid dorsum from the 1st to the 6th ribs in all patients, in 66.7% of patients on the 5th rib level along the paravertebral line, and in 60% of pts the ($-DI_{QRSTmin}$) localization prior to and after RFA coincided. In posterior paraseptal AAVP, the ($-DI_{QRSTmin}$) position was on the 5th rib level along the paravertebral line in 42% of cases, on the 6th rib in the right axillary zone in 42.9% of cases, coinciding with the position prior to ablation in 42.9% of cases. In right AAVP the ($-DI_{QRSTmin}$) position was in the lower right part of the thoracic wall in 45.5% of cases, and, note, on the 5th rib level along the paravertebral line in 3

patients (27.2%), coinciding with the position prior to the ablation procedure in 36.4% of pts. In anterior paraseptal AAVP the position in the right part of the front thoracic wall from the 1st to 6th ribs coincided with the position prior to ablation in 1 pt (16.7%).

In patients with hidden WPW syndrome and A-V nodal tachycardia, the differential isointegrated QRS and ST-T maps revealed the differences of the total de- and repolarization processes from normal, both prior to and after the RFA procedure of an AAVP or an accessory intra-nodal conduction path. However, statistically significant differences in DI_{QRS} and DI_{QRST} values were not revealed. Therefore, we have combined these patients in 1 group according to a comparison of SM results prior to and after RFA of arrhythmogenic zones. No difference was revealed in the differential map parameters of these patients prior to and post RFA (Tables 2 and 3).

The T_{min} localization on the thoracic surface prior to RFA was in the normal range, after RFA in 4 pts (40%) was in the normal range, and in 5 patients (50%) on the right anterior thoracic part from the 2nd to 5th ribs.

The comparison of maximum KFK-MB level increase

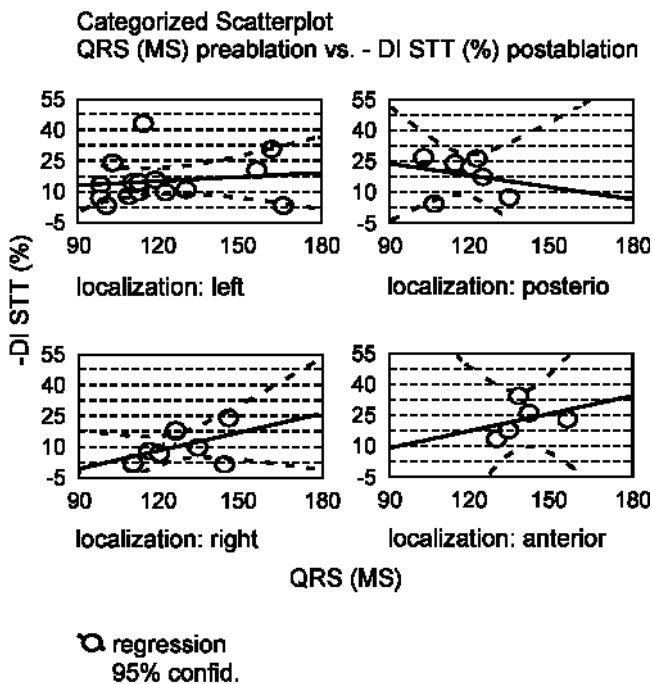


Figure 4. Dependence of surface features of ventricular myocardium repolarization abnormalities after persistent WPW RFA from the preexcitation rate in patients with different AAVP localizations. X-axis: QRS interval duration (ms) prior to RFA of AAVP; Y-axis: $-DI_{ST-T}$, i.e. the amount of negative DI values on differential isointegral maps ST-T (in %).

in patients with persistent WPW and in patients with the hidden WPW form or nodal tachycardia revealed an anomalous increase up to 31.1% in 1 persistent WPW patient (12 RFA applications), and up to 34% in 1 hidden WPW patient (5 RFA applications). On the average no statistically significant differences were revealed for this parameter (17.3 ± 8.7 vs. 12.6 ± 11.8).

Discussion

Surface ECG mapping for the topical diagnosis of persistent WPW syndrome, i.e. anomalous early excitation zone localization, is well known [11-13]. However, the detailed analysis of ventricular myocardium repolarization happens to be more complicated than the ventricular activity study. It is often considered [4,14,15] that QRST integral deviations could supply information on restoration processes. It has been theoretically proven that these QRST distrib-

tions somewhat depend on ventricular activation patterns and reflect mostly distribution of repolarization features in myocardium and their disturbances. Thus, QRST differential maps and DI_{QRST} parameters are widely used in coronary artery disease diagnostics.

There are very few studies concerning the electrocardiographic peculiarities in ventricular repolarization in WPW patients in sinus rhythm. Nicolai et al. [3] discovered that repolarization abnormalities in normal excitation conduction appeared in 87% of patients with persistent WPW syndrome. The minimum localization on the QRST maps differs from normal in 82% of left AAVP cases and in 62% of right AAVP cases, i.e. repolarization in persistent WPW syndrome is anomalous and $DI_{QRSTmin}$ is localized mostly according to the AAVP localization.

While analyzing SM in parietal and septal persistent WPW patients, we have found that surface abnormality features of the repolarization process are not only localized according to the AAVP localization but show different features in different AAVP localization. Table 1 shows that in persistent WPW syndrome not only the direction of the ventricular myocardium activation process changes with the AAVP localisation, but the direction of the repolarization process as well. If the QRS vector bend can be directly related to the onset of the anomalous depolarization process, the ST-T vector in the absence of organic heart disease should follow the QRS vector. However, the ventricular myocardium repolarization process in anterior and posterior paraseptal AAVP is opposite to the depolarization process.

The influence of the localization of the initial asynchronous excitation zone on repolarization can be noticed from the fact that the correlation between the pre-excitation rate and repolarization deviations from normal, expressed by DI, so vivid in the parietal AAVP, is sharply reduced and even changes the sign in paraseptal AAVP (Figure 2).

The specificity of repolarization process features corresponding to different AAVP localization is evidenced also by the specific areas of the thoracic surface where they occur. As can be seen from Figure 3, localization ($-DI_{QRSmin}$), characterizing maximum deflection of myocardium activation from mean-"normal", coincides with the negative delta wave registration area in ECG and is situated on the thoracic surface in the AV sulcus projection zone of the AAVP [13]. At the same time, the ($-DI_{QRSTmin}$) localization, characterizing, as

expected maximum deflection of myocardium activation from mean-"normal", occurs in this area only in 76% of left AAVP cases, and in 67% of right AAVP cases. But only in 16.7% of posterior paraseptal cases the ($-DI_{QRSTmin}$) localization coincides with the negative delta wave zone, in 73.3% of cases coinciding with that of the left AAVP. These results contradict the results of the authors cited above.

The analysis of repolarization process anomalies in persistent WPW syndrome and different AAVP localizations raises the question whether these anomalies decrease with activation process changes. The latter is achieved in clinical practice in WPW patients after RFA and also in the intermittent pathology form. While the post-ablation repolarization features are discussed frequently [4,7-9,15], repolarization features without pre-excitation are treated only in a single study [15], based on SM in 13 intermittent WPW patients.

SM data of our patients with intermittent WPW syndrome showed that differential isointegrated ST-T and QRST maps for the pre-excitation period revealed anomalous differences in integral ventricular myocardium repolarization, in accordance with the data of Nirei et al. [15] in that aspect. Do these anomalies show a relationship to AAVP localization?

We compared our data with those in 13 intermittent WPW patients [15]. The differential QRST maps without pre-excitation revealed the coincidence of ($-DI_{QRST}$) distribution in 1 right AAVP case, in 1 posterior septal case, and in 1 left AAVP case. Notice that the ($-DI_{QRSTmin}$) distribution coincidence with and without preexcitation was observed only in 2 of our patients with left AAVP. Here the anomalous negative T-wave disposition without pre-excitation coincided with the negative delta wave registration area on ECG in 30% of cases - in right and anterior/posterior septal AAVP (Figure 3).

Perhaps the lack of a definite correlation between mentioned anomalies of the ventricular repolarization process and asynchronous activation zone in the presence of pre-excitation was determined by deviations of the ventricular myocardium depolarization process which were not considered by Nirei et al. [15], but could be seen on differential isointegratal QRS maps in 70% of our cases. The integral depolarization process was within the "normal" range only in 3 (30%) of our patients (one pt left, one pt posterior septal and one pt right AAVP).

The achieved results could not be the basis for a statis-

tically significant conclusion due to the insufficient number of observed patients. However, they testify the preservation of myocardium de- and repolarization anomalies immediately after the depolarization pattern changes in young patients without organic heart diseases. The time interval for intermittent WPW syndrome cases was 24 hours. The supposition that repolarization abnormalities without preexcitation are due to the "cardiac memory" phenomenon can not be considered valid, in so far as retained ventricular depolarization disturbances can not be ruled out.

ST-T segment changes on ECG maps after RFA of persistent WPW syndrome have been discussed in several publications [4,7-9,15]. It has been shown that ST-T changes after successful RFA appear mostly in persistent WPW and are practically not observed in hidden AAVP. Moreover, these ST-T changes are temporary and gradually disappear in 6 weeks to 3 months. The authors have discovered that temporary repolarization abnormalities depend on delta wave polarity on ECG and the pre-excitation rate prior to RFA of AAVP.

In addition, the authors have discovered [8] that the post-ablation T-wave abnormality existed in 7 right AAVP patients and did not exist in 12 left AAVP patients. The majority of the authors believe that post-ablation ventricular repolarization changes are due to the continuous influence of electrophysiological process disturbances existing prior to ablation, i.e. they are due to the "cardiac memory" phenomenon.

In our study, the anomalous negative T wave, localized in the same thoracic area where the pre-ablation negative delta wave was registered, was observed in 80% of anterior paraseptal AAVP. And it was observed only in 53.3% of left AAVP cases. Comparison of the ($-T_{min}$) localization after the RFA of intermittent AAVP and in absence of pre-excitation also does not establish a definitive conclusion.

The quantitative evaluation of different QRST maps coincided in general with those of other authors: after RFA of AAVP of all localizations, except the right one. The amplitude and ($-DI_{QRST}$) deflection range are retained. In the right AAVP, these differential QRST map parameters were significantly reduced, although the deflection range was greater in patients with non-persistent WPW. Note, patients with normal QRS and QRST maps after RFA were in each AAVP group (Table 3).

However, the ($-DI_{QRSTmin}$) localization analysis after the RFA of AAVP differs from that described in papers

[4,9,15]. Pre- and post-ablation ($-DI_{QRSTmin}$) localization coincided with 60% only in left AAVP patients, - for other localizations coincidence was in less than 50% of cases.

Is it possible to agree with the following statement: "the more the preexcitation rate prior to ablation, the more distinct repolarization abnormalities after ablation?" In publications [4, 9], the mean QRS interval duration in right and left AAVP patients and differential map parameters like ($-DI_{QRSTmin}$) and ($-DI_{QRST}$) in % were studied. Higher QRS parameters in the right AAVP group corresponded to higher parameters of differential maps. Analyses of a possible correlation of post-ablative differential map parameters with the preexcitation rate in each group of our patients have shown that in the right AAVP localization, in contrast to other AAVP localization, the influence of the pre-excitation rate on repolarisation deviations from "norm" is more probable both prior to and after ablation.

Thus, we have shown that isointegratal QRS maps became practically "normal" only in some of the patients, though the post-ablative surface distributions, corresponding to ventricular activation normalized, and their parameters significantly changed.

The question still remains whether the post-ablative repolarization disturbances refer to secondary T-wave disturbances, i.e. they are caused by disturbances in ventricular myocardium activation patterns.

Our investigations have shown no statistically significant differences in KFK-MB level increase in persistent and in hidden WPW patients. However, the test with structural protein troponin Tn I, that has a specificity and sensitivity higher than those of the KFK-MB test, reveals ablative myocardium distractions, as stated in [16]. Therefore, we can surmise that in post ablative abnormalities of the repolarization process the myocardium distraction after RFA plays a definite role. Further investigations may prove this supposition.

A repolarization anomaly after RFA of the manifesting AAVP becomes more evident in patients as the pre-excitation rate increases, but not completely. The AAVP and other specific anatomic and electrophysiologic characteristics of the anomalous pathway also play a role.

Conclusion

- A ventricular repolarization abnormality expressed in the process of changing direction and dependent

on AAVP localization exists in persistent WPW syndrome. In parietal AAVP the anomaly depends on the pre-excitation rate as well.

- The direction of the ventricular myocardium repolarization process is opposite to the depolarization direction in paraseptal anterior and posterior AAVP. The difference of the QRS and ST-T electric axes ($EOS_{QRS} - EOS_{ST-T}$) can serve as an additional diagnostic feature to localize an anomalous conduction path and to discriminate paraseptal and parietal AAVP.
- In patients with intermittent WPW syndrome from the pre-excitation period, the differential isointegral ST-T and QRST maps reveal repolarization changes deviating from normal; in the absence of the delta wave manifestations of these changes differ with the AAVP localization.
- If the effects on the myocardium are equal during the RFA of supraventricular arrhythmias, the post-ablation repolarization anomalies are more evident in patients with persistent pre-excitation syndrome.
- Post-ablative abnormalities of the myocardium repolarization pattern are caused mostly by anomalous characteristics of myocardium depolarization. Just after RFA the localization of maximum and minimum STT integral values over surface ECG in patients with septal, anterior, and posterior paraseptal and left AAVP localisation coincide, respectively, with the localization of maximum and minimum delta wave values prior to RFA.

References

- [1] Bockeria LA. Tachyarrhythmias. Diagnostics and surgical treatment. Meditsina 1989 (in Russian).
- [2] Koushakovskii MS. Heart arrhythmias. St-Petersburg: Foliant 1998 (in Russian).
- [3] Mandela VG (ed). Heart arrhythmias. Meditsina 1996 (in Russian).
- [4] Gallagher JJ. In: Zipes DP, Jalife J (eds). Variants of preexcitation. in cardiac electrophysiology and arrhythmias. Orlando, 1985.
- [5] Nicolai P, Medvedovsky JL, Delaage M, et al. Wolff-Parkinson-White syndrome: T wave abnormalities during normal pathway conduction. J of Electrocardiol. 1981; 14: 295-300.
- [6] Hirai M, Tsuboi N, Hayashi H, et al. Body surface distribution of abnormally low QRST areas in patients with in Wolff-Parkinson-White syndrome. Evidence for continuation of repolarization abnormalities before and after catheter ablation. Circulation. 1993; 88(6): 2674-2684.

- [7] Inaba-Sato F, Hirai M, Hayashi H, et al. Relationship between QRS duration and repolarization abnormalities in patients with Wolff-Parkinson-White syndrome. *J Electrocardiol.* 1996; 29(4): 301-308.
- [8] Zipes D. Catheter ablation of arrhythmias. Armonk, NY: Futura Publ Comp Inc 1994.
- [9] Kalbfleish SJ, Sousa J, El-Atassi R, et al. Repolarization abnormalities after catheter ablation of accessory atrioventricular connections with radiofrequency current. *J Am Coll Cardiol.* 1991; 18: 1761-1766.
- [10] Wood MA, Di Marco JP, Haines DE. Electrocardiographic abnormalities after radiofrequency catheter ablation of accessory bypass tracts in the Wolff-Parkinson-White syndrome. *Am J Cardiol.* 1992; (70): 200-204.
- [11] Helguera ME, Pinski SL, Sterba R, et al. Memory T waves after radiofrequency catheter ablation of accessory atrioventricular connections in Wolff-Parkinson-White syndrome. *J Electrocardiol* 1994; 27(3): 243-249.
- [12] Tomita Y, Hirai M, Yanagawa T, et al. Body surface distribution of significant changes in QRST time-integral values after radiofrequency catheter ablation in patients with Wolff-Parkinson-White syndrome. *Am J Cardiol.* 1996; 77(1): 59-63.
- [13] Rosenbaum MB, Blanco HH, Elizari MV, et al. Electrotonic modulation of the T wave and cardiac memory. *Am J Cardiol.* 1982; 50: 213-232.
- [14] Benson DW, Sterba R, Gallagher JJ, et al. Localization of the site of ventricular preexcitation with body surface maps in patients with Wolff-Parkinson-White syndrome. *Circulation.* 1982; 65: 1259.
- [15] Kamakura S, Shimomura K, Ohe T, et al. The role of initial minimum potentials on body surface maps in predicting the site of anomalous pathway. *Circulation.* 1986; 74: 89-96.
- [16] Bockeria LA, Revishvili ASH., Polyakova IP, et al. New method of topical diagnostics of accessory conduction pathways in patients with the Wolff-Parkinson-White syndrome. 1989; 7: 49-53.
- [17] Mirvis DM. Body surface mapping. Boston 1988.
- [18] Abildskov JA, Lux RL. Distribution of QRST deflection areas in relation to repolarization and arrhythmias. *J Electrocardiol.* 1991; 24: 197-203.
- [19] Nirei T, Kasanuki H, Ohnishi S, et al. Cardiac memory in patients with intermittent Wolff-Parkinson-White syndrome. *J Electrocardiol.* 1997; 30: 323-329.
- [20] Madrid AH, del Rey JM, Rubi J, et al. Biochemical markers and cardiac troponin I release after radiofrequency catheter ablation: approach to size of necrosis. *Am Heart J.* 1998; 136: 948-955.