

# Implantation of a Coronary Sinus Electrode for Permanent Left Ventricular Stimulation - A Case Report

J. WITTE, G. BAUMANN

Medical Clinic, Charité Hospital, Humboldt-University Berlin, Germany

A. STÜRZENBECHER

Institut für Radiologie, Campus Charité Mitte Hospital, Humboldt-University Berlin, Germany

## Summary

*In the meantime several publications report on left ventricular stimulation, which offers new therapies in cardiac pacing. However, some obstacles such as lead technology still need to be overcome. We report of an implantation of a left ventricular sited electrode placed in the coronary sinus. The patient, where several syncopies were observed, had an indication for pacemaker implantation. Conventional implantation technique was not applicable, since the patient had tricuspid valve replacement. Therefore, she received a standard DDD pacemaker, a standard atrial electrode and a custom designed coronary sinus lead. Good pacing and sensing parameters were achieved with 1.2 V/0.5 ms and 20 mV respectively. They were confirmed at two follow-up procedures one week and a month after the implantation. No dislocation of the lead was detected. Thus, the patient could be supplied with dual chamber pacing therapy despite her artificial tricuspid valve.*

## Key Words

Left-ventricular stimulation, coronary sinus electrode

## Introduction

Since many years, pacemaker implantation is acknowledged as the appropriate therapy for several cardiac disorders. Partially due to improving technology the indication range for pacing therapy still is increasing. This proves to be a challenge for both cardiologists and technicians. State-of-the-art pacing systems from today are not able to deal with the demands arising from interventricular conduction problems. Recent studies, however, reported on an approach of the left ventricle via the coronary sinus. Indications, which require this kind of therapy are congestive heart failure, left bundle branch block and dilative cardiomyopathy [1-5]. The general benefits for patients suffering from these diseases are a resynchronisation of the right and left ventricle and thus an improved hemodynamic. The major drawback to now, however, is to find access to an appropriate stimulation site. Some solutions are reported in publications with refined electrode designs and implantation techniques [6-8]. The clinical endeavours are now focussed on the develop-

ment of easier to handle transvenous leads. We describe the implant of a custom designed transvenous coronary sinus lead. Left ventricular pacing indication, however, in this case was due to existing tricuspid valve replacement.

## Indication and implantation

The 56 year old female patient presented a history of rheumatic fever as a child with the outcome of both mitral and tricuspid failure. In the age of 17 years she suffered from cerebral embolism with a high degree of restitution. Both the mitral and the tricuspid valve were then replaced 1981 and 1990 respectively. She was now admitted to the hospital for two syncopes. During a 24-hour-Holter episodes of sinoatrial block for 6 to 10 seconds were documented. Furthermore she suffered from paroxysmal bradyarrhythmic atrial fibrillation and sinus node arrest. Herewith she had indications for pacemaker implant.

A right-ventricular pacing lead, however, was not feasible due to the artificial tricuspid valve. Furthermore, the patient rejected thoracotomy for epicardial electrode implantation.

Therefore we implanted a custom designed coronary sinus lead (CS) to ensure pacing therapy without affecting the tricuspid valve. The pacemaker was a Logos. In the atrium we placed the standard screw-in electrode YBP-53 (all Biotronik, Germany). The design of the CS lead was adopted from the CS lead used for biatrial stimulation. The implantation team took advantage of the great experience they have in placing this CS lead for biatrial stimulation [9].

The lead is equipped with a left handed silicone screw, in which the stimulation electrode is situated.

### Results

There were no complications at implant and time duration for placement of the lead was short (150 seconds for fluoroscopy). The CS and the atrial leads, their final positionings and the pathway of the CS lead

through the Coronary Sinus vene are shown in Figure 1 and Figure 2.

No dislocation of the CS lead was observed until the first follow-up. The pacing threshold of the left ventricular coronary sinus electrode was 1.2 V/0.5 ms, the sensed potential was above 20 mV. Through a one and a four-week follow-up thresholds stayed stable.

### Conclusion

Left ventricular stimulation is an promising option in the therapy of cardiomyopathies, here especially for treatment of left bundle-branch block and mitral regurgitation. Furthermore, this form of pacing the left ventricle is interesting in all cases, in which conventional electrode implantation is not possible. An easily and reliably applied electrode — as the one introduced in this case report — will extend the field of left sided pacing. New possibilities may arise even for implantable cardioverter defibrillator therapy as for better detection of ventricular tachyarrhythmia in certain cases.

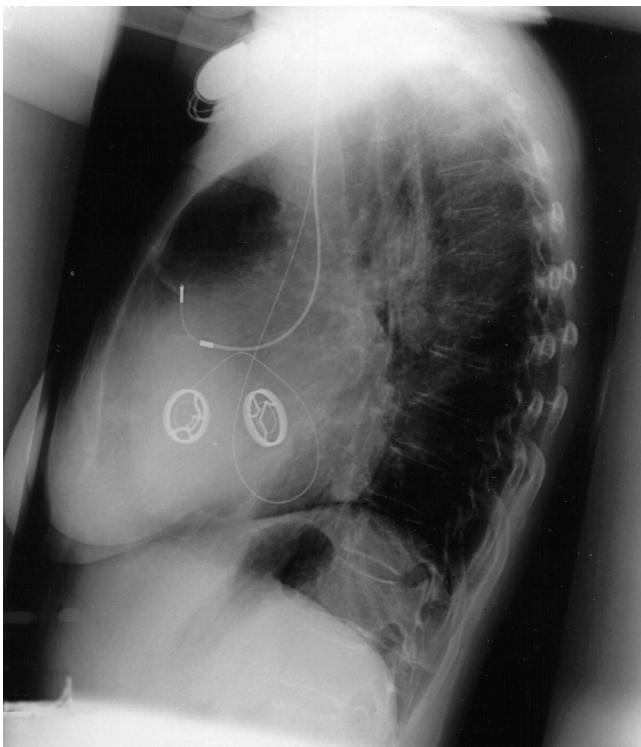


Figure 1. X-ray from the left oblique view, ventricular electrode follows the coronary sinus.

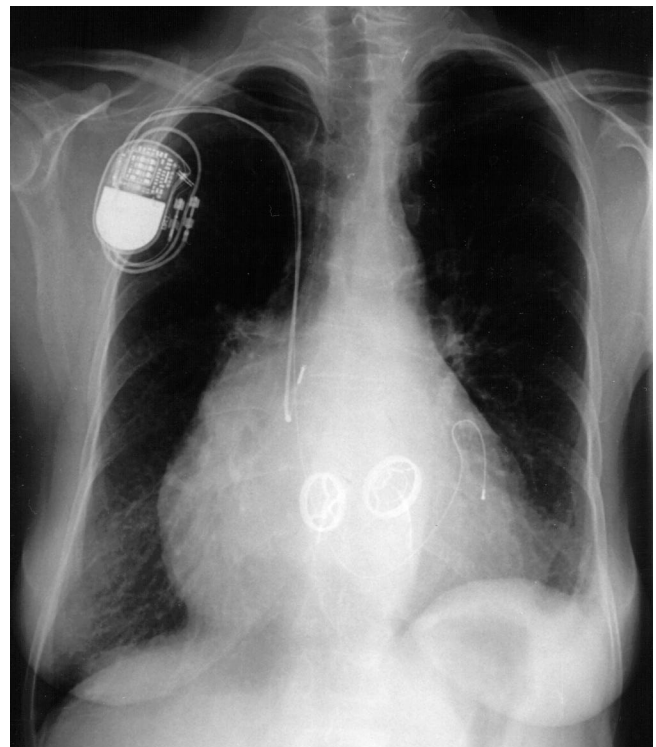


Figure 2. X-ray from the anterior view, ventricular electrode ends just below the valvular plane.

---

**References**

- [1] Gras D, Mabo P, Tang T, et al. Multisite Pacing as Supplemental Treatment of Congestive Heart Failure: Preliminary Results of the Medtronic Inc. InSync Study. *Pace*. 1998; 21 (II): 2249-2255.
- [2] Daubert J, Ritter P, Gras D, et al. Use of specifically designed coronary sinus leads for permanent left ventricular pacing: Preliminary experience. (abstract) *Pace* 1997; 20 (II): 1054.
- [3] Saxon L, Boehmer J, Hummel J, et al. Biventricular Pacing in Patients with Congestive Heart Failure: Two Prospective Randomized Trials. *Am J Cardiol*. 1999; 83: 1250D-123D.
- [4] Auricchio A, Stellbrink C, Sack S, et al. The Pacing Therapies for Congestive Heart Failure (PATH-CHF) Study: Rationale, Design, and Endpoints of a Prospective Randomized Multicenter Study. *Am J Cardiol* 1999; 83: 130D-135D.
- [5] Le Franc P, Klug D, Lacroix D, et al. Triple Pacemaker for End-Stage Heart Failure in a Patient with a Previously Implanted Automatic Defibrillator. *Pace* 1998; 21: 1672-1675.
- [6] Blanc J, Benditt D, Gilard M, et al. A Method for Permanent Transvenous Left Ventricular Pacing. *Pace*. 1998; 21 (I): 2021-2024.
- [7] Auricchio A, Klein H, Tockman B, et al. Transvenous Biventricular Pacing for Heart Failure: Can the Obstacles Be Overcome? *Am J Cardiol* 1999; 83: 136D-142D.
- [8] Daubert J.C, Ritter P, Le Breton H, et al. Permanent Left Ventricular Pacing With Transvenous Leads Inserted Into the Coronary Veins. *Pace* 1998; 21: 239-245.
- [9] Witte J, Reibis R, Bondke H.J, et al. Biatial Pacing for Prevention of Lone Atrial Fibrillation. *Prog Biomed Res*. 1998; 4 (3): 193-196.