

The Prognostic Value of Right Atrial Monophasic Action Potential After Conversion of Atrial Fibrillation

P. POLGÁR, F. WÓRUM, P. KOVÁCS, I. LORINCZ, G. Y. KAKUK
1st Department of Medicine, University Medical School Debrecen, Debrecen, Hungary

Summary

21 patients have been investigated by recording the right atrial monophasic action potential (MAP) after conversion of atrial fibrillation. 14 patients maintained sinus rhythm for more than six months and had an MAP duration in the same range as is found in patients free from atrial fibrillation. 7 patients had an MAP duration shorter than the fibrillation free group, they relapsed into atrial fibrillation within four months. We found that the duration of the right atrial MAP, measured after conversion of atrial fibrillation has a prognostic value in the sinus rhythm stability not only for 3 months, but at least for a period of six months.

Key Words

Atrial fibrillation, monophasic action potential, prognosis

Introduction

In the study of electrical phenomena of individual heart cells the microelectrode technique, which was introduced in 1949 by Ling and Gerald, has become invaluable [1,4]. Due to the fragility of the microelectrode, the action potential (AP) cannot be recorded from the intact heart.

In the past years, the suction electrode technique has become a simple, safe and easily reproducible method for recording the monophasic action potential (MAP) of the intact human heart [5]. The MAP in many respects is similar to the AP recorded from the same place. MAP and AP can be compared with each other with respect to configuration, duration, and amplitude [3]. In 1971, Olsson et al. suggested that the duration of the right atrial MAP can be of prognostic value in the determination of long term results after DC conversion of atrial fibrillation.

Our aim was to study and determine the prognostic value of right atrial MAP after DC conversion of atrial fibrillation.

Material and method

21 patients, suffering from atrial fibrillation for the first time, were investigated using right atrial MAP

recordings. All cases were admitted for therapeutic DC conversion of atrial fibrillation and were informed about the procedure.

The DC conversion was performed during light Sombrevine anaesthesia. At the time of conversion attempt none of the patients were premedicated with chinidin, and digitalis treatment had been stopped the day before the investigation. The DC shock was performed by a Hellige Servocard external defibrillator. The energy amounts for restoring sinus rhythm varied between 100 and 400 Joules.

The right atrial MAP was recorded from the mid lateral wall continuously up to two minutes with the exception of a 5 to 15 sec period, during which the DC shock was applied and the input of the amplifiers used for MAP and intracardiac electrogram recording were disconnected. We used our self-devised suction electrode catheter for recording the MAP of the right atrium [6]. The recording of MAP was performed at a paper speed of 100 mm/sec.

During sinus rhythm the amplitude of right atrial MAP was measured and expressed in mV. The duration of the right atrial MAP was measured at 90% repolarisation and expressed in msec. All calculations during sinus rhythm were performed from 5 beats during

Case No.	Age (years)	Sex	AF duration	Dur. MAP RA (msec)	Ampl. MAP RA (mV)	SR maintenance
1.	60	F	3 months	150	9.2	2 weeks
2.	67	M	2 months	235	11.2	6 months
3.	52	M	6 weeks	205	10.4	6 months
4.	48	M	5 months	180	8.4	3 months
5.	46	F	2 months	255	9.5	6 months
6.	70	M	1 months	215	9.8	6 months
7.	67	M	5 months	190	10.8	4 months
8.	64	F	2 months	210	11.3	6 months
9.	45	M	2 months	280	10.2	6 months
10.	48	F	3 weeks	240	10.5	6 months
11.	66	M	2 months	230	9.3	6 months
12.	60	M	4 months	215	10.0	6 months
13.	61	F	5 months	160	12.1	1 week
14.	49	F	4 weeks	245	13.5	6 months
15.	54	M	2 months	175	12.1	2 months
16.	68	M	3 months	150	14.0	5 days
17.	71	M	1 month	215	11.3	6 months
18.	63	M	4 months	165	9.9	3 weeks
19.	45	F	2 months	250	14.8	6 months
20.	48	M	1 month	235	12.4	6 months
21.	51	F	3 weeks	280	9.8	6 months

Table 1. Results of the analysis of right atrial MAP during sinus rhythm just after the DC conversion of atrial fibrillation.

which the cycle length was not allowed to deviate more than $\pm 10\%$ of the mean value.

After the therapeutic DC shock, we controlled our patients for a six months period at least.

Results

14 patients maintained sinus rhythm for more than six months and the other patients had relapsed to atrial fibrillation before the end of six months post conversion. For further details see Table 1, where we summarized our results.

The right atrial MAP duration ranged between 150 and 190 msec in patients who relapsed into atrial fibrillation within 6 months. This range is far below the corresponding range in patients free from known episodes of atrial fibrillation. Patients, who maintained sinus rhythm for at least 6 months after DC conversion, had

an MAP duration between 205 and 280 msec, which is within the range of arrhythmia free patients [5].

The amplitudes of MAP potentials obtained in our evaluations were between 8.4 and 15.4 mV.

Figure 1 depicts the MAP from the right atrium recorded during atrial fibrillation in case 13. Figure 2 shows the right atrial MAP from the same patients and from the same place after therapeutic DC conversion.

Discussion

Several different clinical details in the patient histories are of prognostic value for maintenance of sinus rhythm after DC conversion.

The duration of an MAP is a good approximation of the duration of an action potential recorded from the same tissue with the microelectrode [2]. There is a relationship between the duration of the action poten-

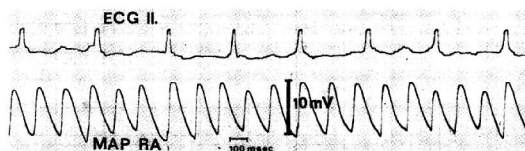


Figure 1. Routine ECG lead and right atrial MAP during atrial fibrillation (case 13).

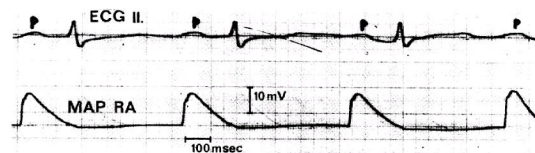


Figure 2. Routine ECG lead and right atrial MAP during sinus rhythm a few minutes after conversion of atrial fibrillation (case 13).

tial and the refractory period [3]. A short refractory period favours the development of an arrhythmia [7]. The purpose of our investigation was to evaluate, whether or not the right atrial MAP can be of prognostic value in the determination of long-term results after DC conversion of atrial fibrillation.

We found, that the duration of right atrial MAP, measured after conversion of atrial fibrillation, has a prognostic value in sinus rhythm stability not only for 3 months — as stated by Olsson et al. [5] — but for a period of six months.

References

- [1] Hecht, HH, et al. 1957: The electrophysiology of the heart. *Ann. N.Y. Acad. Sci.* 65: 653.
- [2] Hoffman, BF, et al. 1959: Comparison of cardiac monophasic action potentials recorded by intracellular and suction electrodes. *Amer J Physiol.* 196: 1297.
- [3] Hoffman, BF, Cranefield, PF. 1960: *Electrophysiology of the Heart.* McGraw-Hill, New York, 1960.
- [4] Ling, G. Gerald, RW. 1949: The normal membrane potential of frog sartorius fibers. *J.cell.comp. Physiol.* 34: 383.
- [5] Olsson, SB, et al. 1971: Monophasic Action Potential and Sinus Rhythm Stability After Conversion of Atrial Fibrillation. *Acta med.scand.* 190: 381.
- [6] Polgár, P, et al. 1979: Improved Quadripolare Suction Electrode Catheter for Recording Monophasic Action Potentials and Stimulation of the Heart. In: *Proceedings of the VIth World Symposium on Cardiac Pacing*, Chap. 4-7. Ed: Claude Meere, Montreal.
- [7] Watanabe, Y, Dreyfus, LS. 1968: Newer concepts in the genesis of cardiac arrhythmias. *Amer Heart J.* 76: 114.