

First Transvenous ICD Implantation in Lithuania

A. KIRKUTIS, J. BREDIKIS, R. KIETZMANN

Seamen's Hospital 1, Cardiology Department for Congenital (Dilated) Cardiomyopathy, Klaipeda, Lithuania

Summary

This paper discusses the first implantation of an implantable cardioverter-defibrillator in Lithuania. The patient had already been implanted with a DDDR pacemaker (Elite-2, MEDTRONIC) for the treatment of congenital sick sinus syndrome with poor AV conduction. Upon entering our clinic with complaints of suddenly arising weakness, shortness of breath, and pain in the chest, the patient soon developed ventricular fibrillation. An electrophysiological exam indicated that the patient should be implanted with an implantable cardioverter-defibrillator. We implanted the Phylax 06 ICD with SPS 75 lead (BIOTRONIK). The flexible lead could be placed in the difficult pathological anatomy of the superior vena cava. Additionally, the small size of the ICD, the noninvasive electrophysiologic study functions, and the bradycardia therapy options suited the patient's needs optimally.

Key Words

implantable cardioverter-defibrillator, transvenous ICD lead, ventricular tachycardia, ventricular fibrillation

Introduction

The patient discussed in this paper was admitted to the Klaipeda Seamen's hospital on July 14, 1998. His medical history included drug-resistant sustained ventricular tachycardia, a six-year history of bradycardia (38 to 45 bpm) and sinus node syndrome (SSS) with poor AV conduction. In 1994, the patient was implanted with a permanent DDDR pacemaker (Elite-2, MEDTRONIC). At three months and one month before admission, the patient had two previous episodes with significant runs of heart rhythm. The first time, tachycardia terminated spontaneously after one hour. The second time, normal rhythm was restored after distribution of amiodarone and lidocaine IV.

Regarding the family history of the patient, his sister (at age 18) died of sudden cardiac death 5 years ago. Her death prompted an examination of the patient, with the diagnosis of the sinus node syndrome with poor AV conduction. The autopsy revealed that the heart of the sister showed fibro-elastosis with thickened right and left ventricular walls. Furthermore, the father of the patient worked for many years on an atomic submarine and had contact with nuclear radiation before his children were born.

Materials and Methods

On July 14, 1998, the patient (male, 18 years of age) entered the clinic with complaints of suddenly arising weakness, shortness of breath, and pain in the chest. Physical examination revealed dyspnea, cyanosis, a blood pressure of 80/60 mmHg, a pulse of more than 200 bpm, and a respiration rate 36 min⁻¹. The veins in his neck were distended. Chest examination revealed inspiratory edema. The liver was enlarged and tender to palpitation. Extremities were cool and without edema. The ECG indicated dissociated P-wave activity and regular wide QRS VT at a rate of 250 bpm. The patient was admitted to the intensive care unit when he subsequently developed hemodynamically significant runs of sustained VT at 250 bpm. Potassium and magnesium serum was administered. Medication with an IV bolus of 100 mg of lidocaine was administered for more than 2 min and an additional 100 mg IV was delivered 5 min later in addition to 450 mg of amiodarone without any effect. The patient suddenly developed ventricular fibrillation with no pulse or blood pressure. Immediate transcutaneous electrical defibrillation at 300 J was performed and sinus rhythm at 60 bpm was restored.

Once the heart rhythm of the patient stabilized, he was transferred from the intensive care unit to the cardiology department where several investigations were performed. Echocardiography revealed poor inotropy overall, akinesia in the apex of the left ventricle (LV), hypokinesia in the anterior and lateral LV wall. The volume of the right-heart cavities were less than those of the left heart. The aorta was 2.9 cm in diameter, the LV (diastolic), 7.1 cm. The LV posterior wall was 0.8 cm in thickness, the interventricular septum, 0.9 cm. The dimensions of the right atrium were 4.7 cm by 5.3 cm, the left atrium, 6.7 cm by 6.6 cm.

Despite the long-term therapy of 200 mg of amiodarone 3 times daily (taken orally), an invasive electrophysiology study was performed to determine the inducibility of VT and to study the characteristics of the induced tachycardia. Three endocardial electrodes were inserted through the inferior vena cava into the right-heart cavities. Three VT episodes (two with a time-stable morphology and one with polymorphic VT) were induced by programmed electrostimulation at the apex of the right ventricle (RV). The tachycardias were treated with ventricular overdrive stimulation twice and through a 200 J transcutaneous defibrillation shock once.

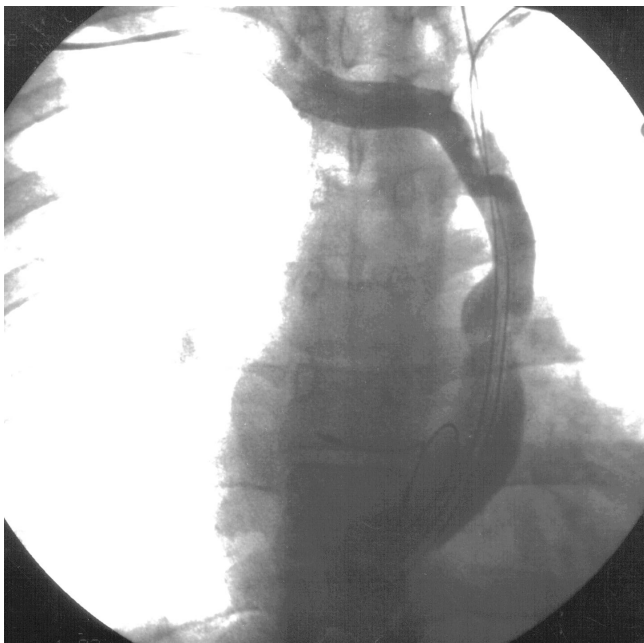


Figure 1. Angiography showed a congenitally pathologic superior vena cava in the left position leading blood from the left side into the coronary sinus and then on into the right atrium.

During a 24-hour Holter ECG monitoring no VT episodes were recorded.

A thoracic x-ray examination showed no significant stasis in the lungs. The unusually placed endocardial electrodes for the DDDR pacemaker (implanted in the left subclavian position) were visible. Angiography showed a congenitally pathologic superior vena cava in the left position leading blood from the left side into the coronary sinus and then on into the right atrium (Figure 1).

Laboratory values include the following: Hb, 153 g/l; L, 6.9 g/l; WBC, 5300 mm⁻³; sodium, 140 mEq/l; potassium, 4.5 mEq/l; chloride, 100 mEq/l; uric acid, 3.1 mg/dl; creatinine 0.8 mg/dl; antistreptolysin test (AST), 46 u/l; alanine-aminotransferase (ALT), 42 u/l; APTT, 39 s.

The decision was made to implant a permanent implantable cardioverter-defibrillator (ICD).

Operative Technique

The patient was placed under novocaine anesthesia. The lead (SPS 75, BIOTRONIK) was inserted in the subclavian vein through a 10-French introducer. In an unusual way, the tip of the lead was advanced to the right-ventricular apex under fluoroscopic guidance and

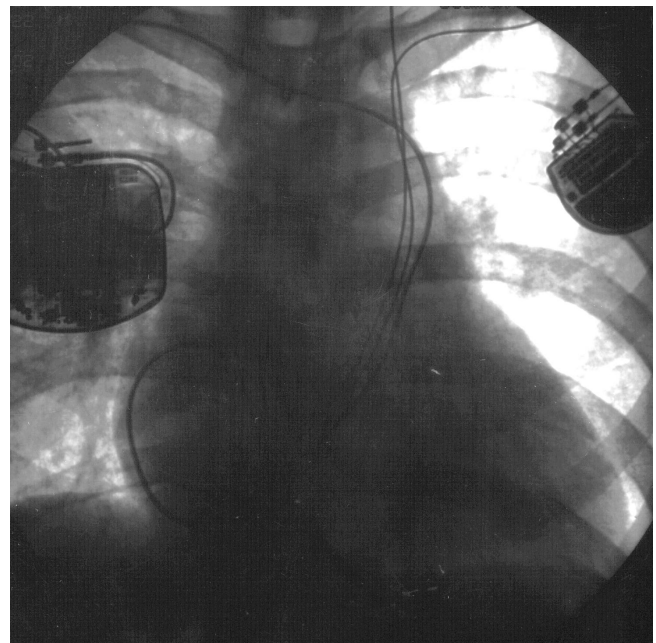


Figure 2. Thoracic x-ray showing the location of the implanted cardioverter-defibrillator, the pacemaker and all leads.

was positioned to achieve adequate pacing and sensing thresholds. The permanently implanted lead was used to induce ventricular fibrillation (VF) by a shock that was delivered during the T wave. VF was then terminated by R-wave synchronous intracardial cardioversion. Once cardioversion thresholds and responses to the shock were found to be adequate, the lead was connected to the Phylax 06 ICD with active housing. With the implanted device, VF was induced again and terminated with synchronized shocks. A subpectoral pocket was created inferior to the right clavicle, and the implantation of the defibrillator was completed (Figure 2).

Postoperative checking of the previously implanted DDDR pacemaker indicated battery depletion. The pacemaker was switched off. On the ECG, sinus rhythm was recorded at 55 to 60 bpm. The ICD was set to the VVI mode at a rate of 45 bpm.

Postoperative 24-hour Holter ECG monitoring revealed no arrhythmia episodes. Sinus node rhythm was present 73% of the time, VVI pacing, 27% (at night). One week after operation, the patient was discharged from the hospital in good condition.

At the one-month follow-up, initiating VT and VF was attempted through the implanted electrode with right ventricle stimulation programmed and T-wave shock being delivered by the cardioverter and controlled by the external programmer. Ventricular tachycardia with a cardiac cycle length 270 ms and ventricular fibrillation were induced. In the first case, cardioversion with rapid ventricular stimulation was effective, and in the second case, an internal cardio-shock with the implanted device.

Discussion

For the first time in Lithuania, the feasibility of transvenous catheter cardioversion with the use of an implanted unit was demonstrated in a patient with recurrent ventricular tachycardia. The other features of the ICD, including its small size, simple implantation, and use for repeated noninvasive electrophysiologic studies and bradycardia pacing functions, make it a valuable device for VT/VF patients. The flexible percutaneous SPS 75 lead could be used in the unusual innate pathology of the superior vena cava.