

First Clinical Experience with a "Cooled" Catheter RF Ablation of Right Ventricular Outflow Tract Tachycardia

A. SH. REVISHVILI, V. A. BAZAEV, U. T. KABAEV, V. V. KUPTSOV, M. V. NOSKOVA
A. N. Bakoulev Research Center for Cardiovascular Surgery, Russian Academy of Medical Sciences, Moscow, Russia

Summary

First clinical experiences with a successful "cooled" catheter radiofrequency ablation of right ventricular outflow tract tachycardia in right ventricle arrhythmogenic cardiopathy (dysplasia) are reported. In the presented case report, 4 applications of conventional radiofrequency ablation at a temperature of 63 to 65 °C led only to a temporary ventricular tachycardia termination; the tachycardia was subsequently re-initiated during pacing in the right ventricle. In contrast, "cooled" radiofrequency ablation, being able to reach arrhythmogenic foci located deeper, resulted in permanent ventricular tachycardia termination. Thus, it offers itself as a possible method of choice for treating tachycardia originating from the right ventricular outflow tract in the case of deep arrhythmogenic focus location.

Key Words

Ventricular tachycardia, arrhythmogenic right ventricle cardiopathy (dysplasia)

Introduction

In 1977, Fontaine et al. were the first to report on arrhythmogenic right ventricle dysplasia as one of the cardiopathy types that affects mainly the right ventricle [1]. This pathology is characterized by adipose myocardium dysplasia of the apex and of the right ventricular outflow tract (RVOT). Ventricular tachycardia (VT) with the morphology of left His bundle block and of left His bundle anterior branch block is caused by this pathology. It has been frequently observed in young patients and poses a risk for sudden death.

The efficiency of radiofrequency ablation (RFA) to treat VT associated with right ventricle arrhythmogenic dysplasia remains unclear. Accordingly, we present a case report of an effective "cooled" RFA in an RVOT tachycardia patient.

Case Report

Patient H, a 20-year old male who complained about tachycardia attacks and increasing weakness, was admitted to the Department for Surgical Tachyarrhythmia Therapy. According to the anamnesis, the first tachycardia attack occurred during physical exer-

cise at the age of 15. This episode lasted several minutes and terminated spontaneously. Later, paroxysmal tachycardia occurred accompanied by a loss of consciousness. Antiarrhythmic drugs (cordarone, sotalol, athenalol, ethmosin, isoptin) were administered without effect. In March 1999, during an electrophysiologic study, RVOT re-entry tachycardia was induced and treated by RFA. No VT episodes developed during the 6 days following the treatment. However, ventricular premature beats (PB) and VTs with a different morphology were registered.

Clinical biochemical analyses were within normal rates.

During sinus rhythm, the electrical heart axis was along + 120 °, the heart rate was 74 bpm, isolated ventricular PBs had left His bundle block morphology. Otherwise, two types of VT were registered: left His bundle block + left His bundle posterior branch block with a cycle length (CL) of 223 ms, and left His bundle block + left His bundle anterior branch block with a CL of 387 ms.

A 24-hour ECG Holter monitoring showed sinus rhythm, a minimum heart rate of 42 bpm during night

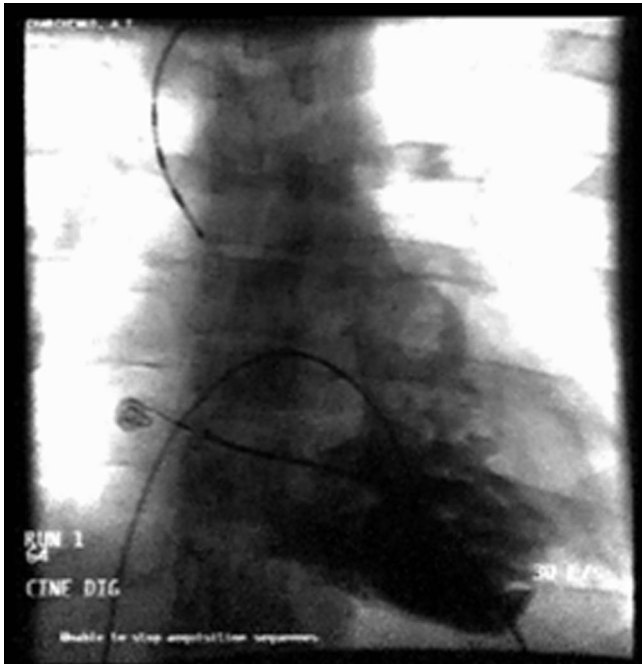

Figure 1. Right ventriculography. A filling defect and probable round aneurysm formation are visualized in the RVOT.

time, and a maximum heart rate of 163 bpm during physical exercise; 45 isolated supraventricular PBs, 6,873 ventricular PBs (6,000 of them isolated), 155 couplets, and 61 VTs with a maximum heart rate of 215 bpm were registered. An X-ray of the lungs revealed no changes, but the right heart was enlarged.

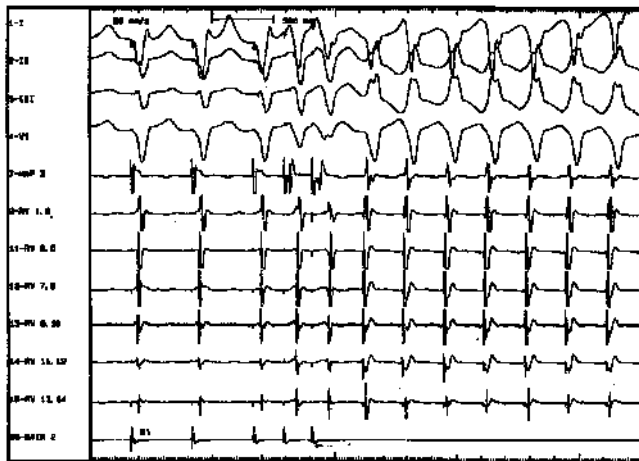


Figure 2a. RVOT VT (CL = 380 ms) with left His bundle block morphology induced by programmed RV apex pacing with two ES (S1 = 500 ms, S2 = 250 ms, S3 = 220 ms).

According to the echocardiography examination, the left heart chambers were not dilated, the ejection fraction was 60 %, the mitral valve had a small regurgitation, but no right heart enlargement could be observed. Manifesting trabeculation, right ventricular (RV) hypertrophy, filling defect and possible aneurysmic dilatation of the RVOT and right ventricle contraction reduction were revealed by right ventriculography (Figure 1).

The electrophysiologic study was carried out using Prucka Engineering (USA) equipment with a 30 to 500 Hz bandwidth.

The right and left femoral veins were punctured under local anesthesia. Three catheters were introduced: a USCI catheter (Bard) was placed into the right ventricular apex, a 20-pole electrode catheter was placed into the RVOT, and an ablation catheter (Marinr MC, Medtronic) was used for VT focus mapping and RFA. A stable monomorphic VT was induced from the RVOT with left His bundle block + left His bundle anterior branch block morphology and a CL = 387 ms by two extrastimuli (ES) in connection with programmed RV apex pacing, which was spontaneously terminated by a ventricular extrasystole (Figure 2a, b). According to the aforesaid, the VT is considered to be of re-entry nature.

Mapping performed at the onset of the tachycardia detected the earliest excitation in the aneurysm isthmus of the RVOT (Figure 3). This excitation, recorded at the place of ablation, preceded the QRS complex by

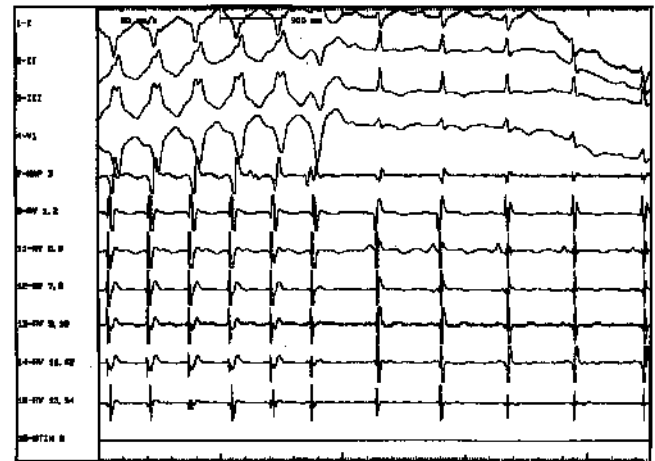


Figure 2b. Ventricular tachycardia terminated spontaneously by a ventricular extrasystole with the V-V1 interval of 320 ms.

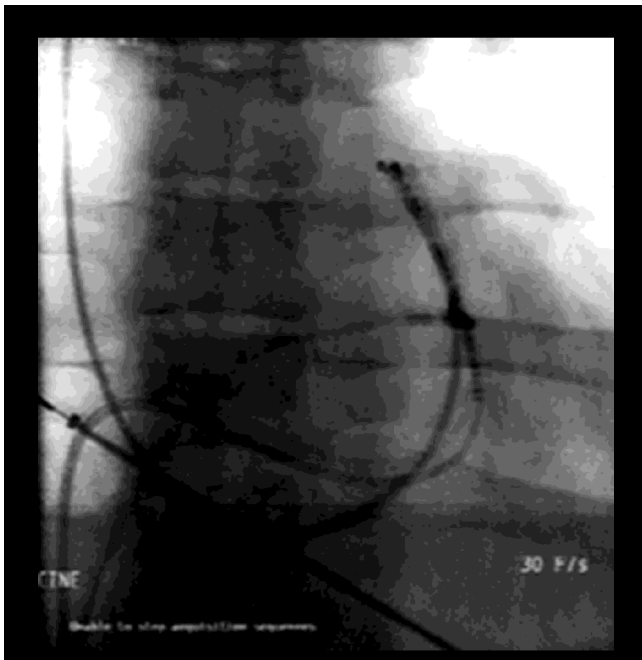


Figure 3. The ablation catheter electrode is positioned in the arrhythmogenic zone of the RVOT (indicated by pointer).

40 ms. The double ventricular potential was registered in the same zone (Figure 4).

Initially, RFA was performed with the Atakr RF generator (Medtronic) in the temperature-controlled mode for 1 min at 60 °C and 50 W. Termination of the VT

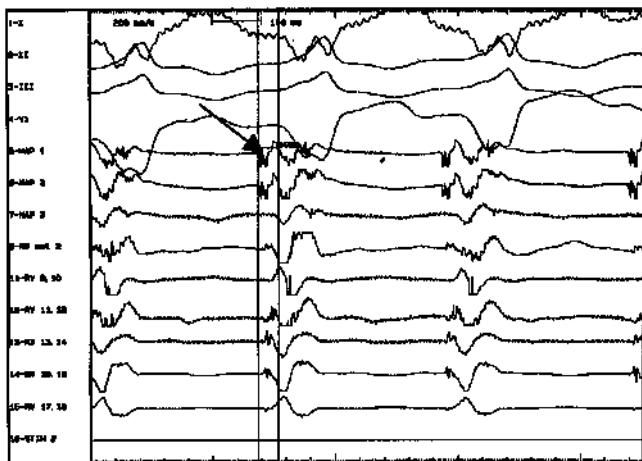


Figure 4. Mapping results at the place of ablation during VT onset. Please refer to the text for explanation. MAP - ablation catheter positioned at the location of the earliest intracardiac signal. RV - a 20-pole catheter positioned at the RVOT.

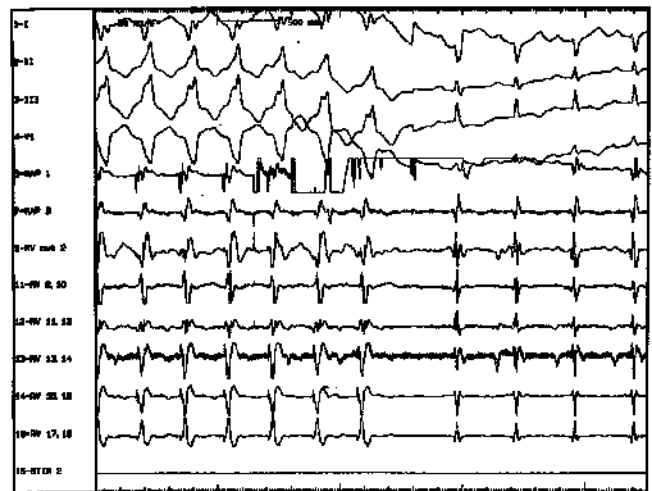


Figure 5. Elimination of the VT observed during the first second of the conventional RFA application at a temperature of 63 to 65 °C.

was observed during the first second of the RFA application at a temperature of 63 to 65 °C with an impedance of 120 to 130 Ω (Figure 5).

Unfortunately, programmed pacing in the right ventricle with the previous parameters induced VT anew. A total of 4 RFA applications, first terminating the VT, then re-initiating it during stimulation, were performed.

Then, the "cooled" RFA technique was applied because of the deep location of the tachycardia focus. An 8004 RF generator in combination with the cooled ablation catheter "Chilii" (both by Cardiac Pathways) was used. According to the X-ray results as well as anatomical and electrophysiologic criteria, the catheter tip was positioned in the earliest tachycardia zone, and a "cooled" RFA was performed (twice for 1 min, at 42 °C, 20 W, with 200 ml cooling solution at a flow rate of 0.6 ml/s). The CL of the tachycardia increased and VT termination was observed in the course of "cooled" RFA with an electrode tip temperature of 40 °C and 120 Ω impedance (Figure 6). No VT from the RVOT could be re-induced by programmed pacing in the right ventricular apex (Figure 7).

Discussion

According to Miles et al. (1998), a right or left ventricular RFA approach could be ineffective in patients with idiopathic VT from the RVOT in the case of a

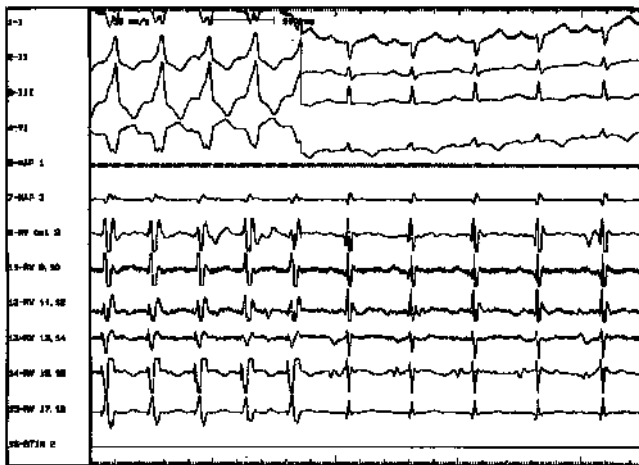


Figure 6. Termination of VT by cooled RFA. MAP - the "cardiac pathways" ablation catheter electrode.

deep arrhythmogenic focus location in the interventricular septum [2].

The discussed clinical case concerned a right ventricle arrhythmogenic cardiopathy (dysplasia) patient with monomorphic, constantly recurrent RVOT tachycardia. In this respect, multiple "hot" RFA attempts had a temporary effect while the "cooled" catheter RFA procedure terminated the tachycardia successfully, thus confirming its deep focus location. Deeper disposition of the radiofrequency energy in the "cooled" ablation technique is probably the reason for its success [3].

Harada et al. (1998) reported that in some cases a re-entry mechanism caused right ventricular idiopathic

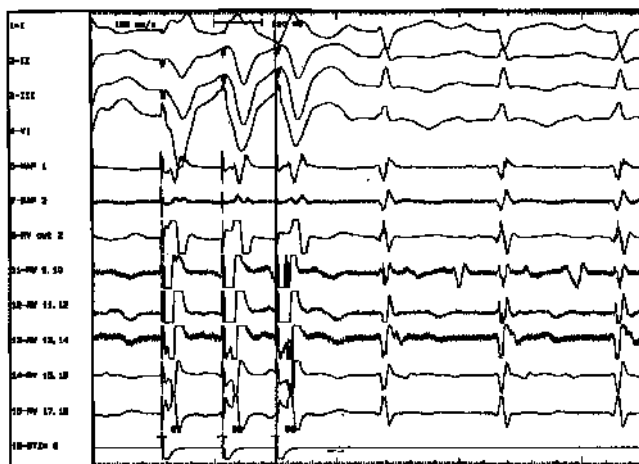


Figure 7. Programmed pacing at the RV apex with two ES ($S1 = 500$ ms, $S2 = 250$ ms, $S3 = 220$ ms) after successful "cooled" RFA of the RVOT VT: no VT could be induced.

arrhythmias and arrhythmias due to right ventricular arrhythmogenic dysplasia [4].

In our case, tachycardia was induced and terminated by programmed RV pacing. The potential registration during mid-diastole at tachycardia and its elimination by RFA application proved the tachycardia mechanism to be re-entry. The low amplitude potential in the successfully ablated area indicates the critical conduction delay zone of the RVOT re-entry circle to be in the aneurysm ostium.

Wilber et al. (1993) and Coggins et al. (1994) announced a radical correction of the Fallot tetralogy after effective RFA of the RVOT VT [5,6]. After successful RFA of idiopathic RVOT VT, they reported that the intracardiac electrogram signal on the ablation catheter at the effective site should precede the onset of the QRS complex by 45 to 100 ms. Our experience shows the earliest intracardiac electrogram signal at the ablation catheter registered 40 ms before the QRS complex. Furthermore, the double ventricular potential was registered in the same zone.

Conclusion

"Cooled" catheter RFA might be the method of choice to eliminate tachycardia originating from the RVOT in the case of deep arrhythmogenic focus location.

References

- [1] Fontaine G, Fontaliran G, Lascault, et al. Arrhythmogenic right ventricular dysplasia. In: Cardiac Electrophysiology: From Cell to Bedside. Zipes DR, Jalife J (eds.). W B Sanders, Philadelphia, 1995: 754-769.
- [2] Miles W, Olgin J. Ablation of idiopathic left ventricular tachycardia. In: Nonpharmacological Therapy of Arrhythmias for the 21st Century. The State of the Art. Singer I, Barold S, Camm A (eds.). Futura Publishing Co., Armonk, 1998: 233-252.
- [3] Panescu D, Fleishman S, Wayne J, et al. Effects of cooled-electrode ablation on maximum tissue temperature. PACE. 1997; 20: 1205.
- [4] Harada T, Aonuma K, Yamauchi Y, et al. Catheter ablation of ventricular tachycardia in patients with right ventricular dysplasia: Identification of target sites by entrainment mapping techniques. PACE. 1998; 21: 2547-2550.
- [5] Wilber D, Baerman J, Oklansky B, et al. Adenosine-sensitive ventricular tachycardia: Clinical characteristics and response to catheter ablation. Circulation. 1993; 87: 126-129.
- [6] Coggins D, Lee R, Sweeney J, et al. Radiofrequency catheter ablation as a cure for idiopathic tachycardia of both left and right ventricular origin. J Am Coll Cardiol. 1994; 23: 1333-1341.